

This excerpt from

What the Hands Reveal About the Brain.
Howard Poizner, Edward Klima and Ursula Bellugi.
© 1990 The MIT Press.

is provided in screen-viewable form for personal use only by members of MIT CogNet.

Unauthorized use or dissemination of this information is expressly forbidden.

If you have any questions about this material, please contact
cognetadmin@cognet.mit.edu.

Chapter 7

Visuospatial Nonlanguage Capacity

In hearing people the right cerebral hemisphere has its own specialized abilities. The right hemisphere is clearly dominant for perception and processing of spatial patterns, spatial relations, and spatial transformations. Our investigation of language capacity in six brain-damaged signers shows that brain organization for a language in the visuospatial mode is in many ways similar to that for a language based on hearing and speech. We have shown that it is the left hemisphere that is specialized for sign language—but do signers display cerebral specialization for nonlanguage visuospatial processing? Spatial relations, transformations, and linguistic structure are intimately intertwined in sign language. Does the acquisition of a language that makes intricate use of visuospatial relations change the organization of the brain for processing nonlanguage visuospatial relations?

When we began the research that forms the basis for this book, little was known about hemispheric specialization for spatial analysis in deaf signers (see Poizner and Battison (1980) for a review). Many studies indicate a greater role for the right hemisphere than for the left hemisphere in deaf as well as hearing subjects in processing visuospatial stimuli, although there has been considerable controversy and quite a number of conflicting results (Kelly and Tomlinson-Keasey 1977; Kettrick and Hatfield 1986; Manning et al. 1977; Neville 1977; Neville and Bellugi 1978; Phippard 1977; Poizner, Battison, and Lane 1979; Poizner and Lane 1979; Samar 1983; Virostek and Cutting 1979). In order to assess the visuospatial abilities of right- and left-lesioned deaf signers, we selected spatial tests that had independently been found to maximally distinguish performance of brain-damaged hearing patients; that is, on these tests, hearing patients with right-hemisphere lesions were impaired compared to those with left-hemisphere lesions. The battery of tests we administered to our six subjects allows us to draw some definitive conclusions about visuospatial capacities in deaf signers.

7.1 *The Effects of Right-hemisphere Damage on a Deaf Artist*

As we mentioned in her case study, Sarah M. had been an accomplished artist before her stroke; she was skilled in painting and the elaborate artwork required in decorating eggshells and ceramics with exquisite designs. We were fortunate enough to obtain photographs of some of her prestroke artwork. The top half of figure 7.1 shows two paintings that Sarah M. executed before her stroke: a tall Indian chief in full headdress, standing, looking out over a hillside and pointing toward something in the distance, and a detail from a field of mountain flowers clustered together. Both paintings utilize strong colors. These paintings provide evidence of Sarah M.'s superior visuospatial capacities before her stroke. The lower half of figure 7.1 shows Sarah M.'s attempts, one year after her stroke, to copy two drawings that are part of our battery of visuospatial tasks. The poststroke drawings, which are barely recognizable without the model present, show severe distortions and omissions. Note the omissions of the head and all but one leg of the elephant and of the left-hand side of the house, the bottoms of the windows, and most of the roof; note also the overwriting of lines in an attempt to reproduce the sidewalk in front of the house. It is as if Sarah M. were attempting to copy pieces of the drawings without an overall spatial organization. This severe loss of her ability to draw after her right-hemisphere stroke brings out in a pronounced way the spatial loss seen in right-lesioned signers across a variety of visuospatial nonlanguage tasks.

7.2 *Nonlanguage Visuospatial Functions*


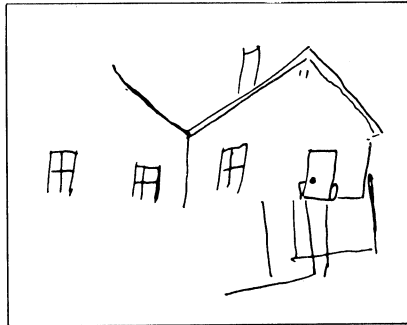
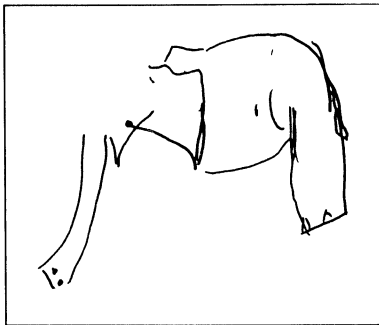
We have carefully selected tests that in hearing individuals discriminate maximally between the performance of right-hemisphere-damaged patients and that of left-hemisphere-damaged patients. Damage to either hemisphere in hearing patients can produce spatial impairment (DeRenzi 1982; Goodglass and Kaplan 1979; Warrington, James, and Kinsbourne 1966). What often differentiates the performance of left-brain-damaged patients from that of right-lesioned subjects is not only the degree of absolute impairment exhibited but also the different types of error made and the different processes used in performing the tasks (Kaplan 1983; Goodglass and Kaplan 1979).

We begin with an analysis of the performance of the six patients on the block designs from the WAIS-R Block Design subtest of the Wechsler Adult Intelligence Scale. We then turn to an analysis of drawings from the parietal lobe battery of the BDAE, performance in copying the Rey-Osterreith complex figure, and tests of unilateral

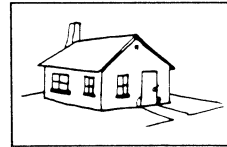
Sarah M.'s prestroke oil paintings.



Sarah M.'s copying of models after her stroke.



MODEL



MODEL

Figure 7.1

Comparison of Sarah M.'s prestroke paintings and poststroke drawings. The spatial deficits shown in Sarah M.'s drawings stand in marked contrast to her good artistic abilities before her stroke, as revealed by her paintings.

neglect. We finally turn to performance on visuospatial tests of facial recognition and line orientation. These tasks tap into the specialized capacities of the right hemisphere, and hence right-hemisphere damage often leads to marked impairment. It is certainly true that spatial analysis does not involve only the right hemisphere; the left hemisphere is also involved, but lesions to the left hemisphere produce qualitatively different and quantitatively less severe impairment. No single performance is taken as definitive; rather, converging evidence from the array of tasks provides the necessary test as to whether or not brain organization for processing nonlanguage visuospatial relations is modified in deaf signers.

7.2.1 *Visuoconstructive Tasks*

For all tasks a native signer instructed the patients in ASL. We recorded their responses on videotape, except in tests requiring them to point to a response-choice card or to sign a response-choice number; these responses were recorded at the time of testing.

Block Design

For hearing patients the WAIS-R block design (Wechsler 1981) has proved to be a sensitive instrument in distinguishing left- from right-brain damage. In this test the subject assembles either four or nine three-dimensional blocks, the surfaces of which are colored red or white or half-red and half-white, to match a two-dimensional model of the top surface. Hearing patients with right-hemisphere damage consistently demonstrate greater impairment than patients with left-hemisphere damage (DeRenzi 1982). Right-hemisphere damage impairs the maintenance of the overall configuration (Ben-Yishay et al. 1971) and increases the likelihood of a piecemeal approach to the problem (Patterson and Zangwill 1944). In contrast, damage to the left hemisphere produces little change in patients' treatment of the overall configuration of the design. Left-lesioned patients do, however, often err on the internal features of the design and tend to make more errors on the right-hand side of the design.

The performance of commissurotomized patients working on block designs with the right hand (reflecting the activity of the left hemisphere in isolation) is comparable to patients with lesions lateralized to the right hemisphere. The constructions of these patients using the left hand (reflecting the capacity of the isolated right hemisphere) is comparable to patients with lesions lateralized to the left hemisphere (Geschwind 1979). Adequate performance on block design, therefore, requires the integrity of both cerebral hemispheres, and a lesion in

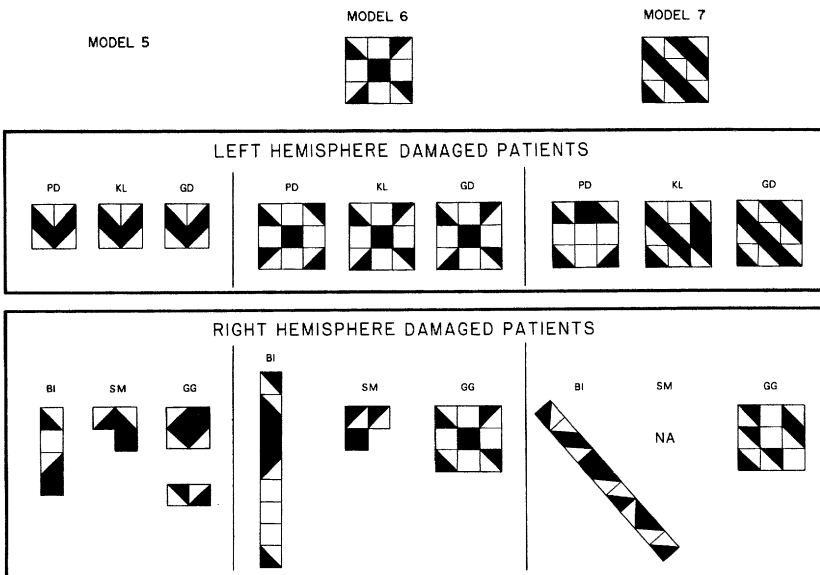


Figure 7.2
Performance on the WAIS-R Block Design Test. Note the broken configurations and severe spatial disorganization of the right-lesioned signers.

either hemisphere produces a distinctive performance that reflects the contribution of the nondamaged hemisphere.

Figure 7.2 presents sample designs produced by six deaf patients we studied. We see that the right-lesioned patients perform differently from the left-lesioned ones; the nature of their designs and the differences between them closely resemble the performances of hearing subjects with lateralized lesions. Each of the three patients with right-hemisphere damage, Brenda I., Sarah M., and Gilbert G., broke the external configuration of the designs. Gilbert G., who had been an airline mechanic before his stroke and therefore was especially skilled in the assembly of complex machine parts from blueprints, did not reproduce any of the designs correctly. Brenda I. broke the external configurations in all nine designs. On design 7 she appears to have attempted to capture the salient feature of the design—the diagonal stripes—by orienting the blocks on the diagonal. This kind of error is often seen in hearing patients with right-hemisphere lesions. Sarah M. produced incomplete, rudimentary constructions and would not even attempt the more difficult designs. Clearly, the performance of the patients with right-hemisphere lesions shows gross

spatial disorganization (despite the fact that they were using their dominant right hands in constructing these designs).

The left-lesioned patients, in contrast, show no broken configurations on any of the designs. As figure 7.2 shows, the errors that they did make in the more complex designs deal with internal features of the design. Their performance closely resembles that of hearing patients with left-hemisphere lesions. Gail D., whose lesion is primarily anterior, had a flawless performance. Karen L., with left parietal involvement, performed well on design 6. The errors she made in design 7 were on the right-hand side of the design; the left-hand side is quite well reproduced. Paul D., who is more severely impaired, made errors on designs 6 and 7; however, on design 6, the major aspect of the figure is preserved, and on both designs the left half is better reproduced than the right.

Thus the impairments demonstrated by both the right- and left-lesioned signers on the revised WAIS-R Block Design test are characteristic ones, similar to those made by hearing patients with comparable lesions.

Drawing Tasks

Hearing patients with left-hemisphere damage characteristically draw a general contour or configuration but leave out internal details and features. Their drawings generally display correct spatial relationships but appear simplified. In contrast, the drawings of hearing patients with right-hemisphere damage are usually replete with details but lacking in overall spatial organization (Goodglass and Kaplan 1979; Warrington, James, and Kinsbourne 1966; Delis, Robertson, and Efron 1986). Also, some people with right-hemisphere lesions characteristically leave the left-hand parts of a drawing unfinished because of hemispatial neglect. Aside from the classic phenomenon of neglect, however, difficulty in the hemiattentional space contralateral to their lesion is common to both left- and right-lesioned patients (Kaplan 1980). The drawings of left-lesioned patients, for example, often contain distortions on the right half of the figure, and the converse is true for right-lesioned patients.

All six patients were asked to draw figures with and without a model; the figures were adapted from the parietal lobe battery of the BDAE. One right-hemisphere-lesioned patient, Gilbert G., did not show dramatic distortions in these drawings, although he did show marked visuospatial impairment on other tasks. Thus we compare the drawings of the three left-lesioned patients and of two right-lesioned patients; we present Gilbert G.'s drawings separately.

In the task without models the patients were asked to draw a clock

(showing numbers, with two hands), a daisy, an elephant, a box (showing three sides), and a house (front and sides), as shown in figure 7.3. The left-lesioned patients drew simplified two-dimensional representations. In many of the drawings the contours are executed in essentially one continuous line, a technique seen most dramatically in the drawings of the elephants and in Gail D.'s daisy. Most distortions appear in the right hemiattentional field. Note, for example, the difference between the right- and left-hand sides of Karen L.'s daisy; the leaves do not join the stem on the right-hand side but do on the left. Similarly, the contour of Karen L.'s elephant is generally correct but distorted on the right-hand side. The characteristics of Karen L.'s and Gail D.'s drawings are consistent with those of hearing patients with damaged left hemispheres. Paul D.'s drawings are the most severely impaired. They are grossly oversimplified and unusually small (note the daisy and the elephant). His box and house

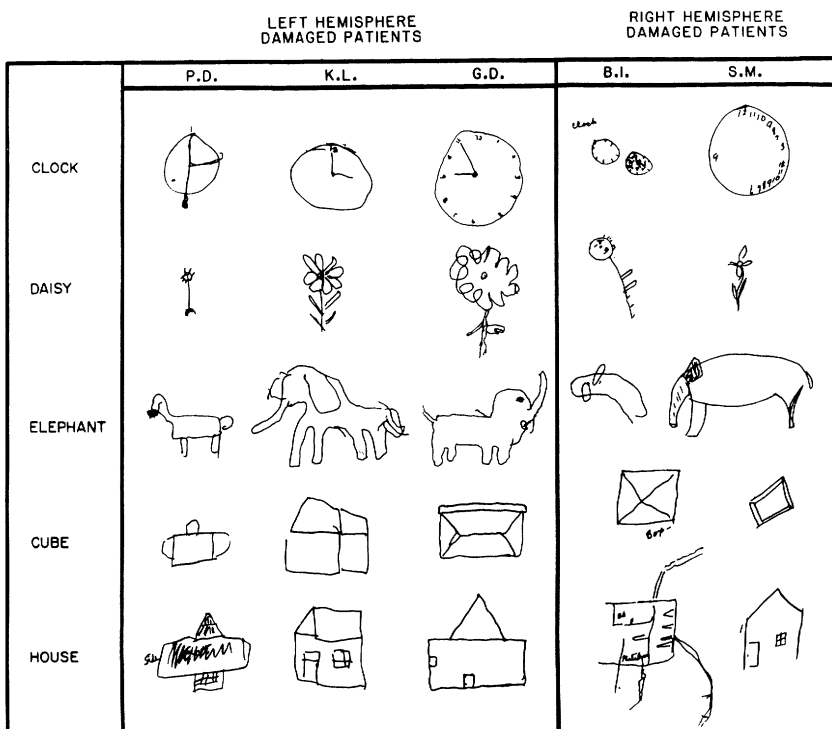


Figure 7.3

Drawing without a model from left- and right-lesioned signers. Note that the right-lesioned signers show severe spatial distortions.

lack perspective. He wrote the words "side" and "front" in response to the examiner's request to indicate these parts. His drawings, however, are equally impaired on each side. Because aging has a greater impact on visuospatial functioning than on language functioning (Hochanadel and Kaplan, in press), Paul D.'s visuospatial impairment may reflect his age more than his left-hemisphere lesion.

The drawings (without models) of the right-lesioned patients Brenda I. and Sarah M. show severe spatial disorganization, with Brenda I.'s the more impaired. There is a focus on component parts at the expense of contour (see Brenda I.'s elephant and house), and the parts are not related well spatially to each other or to the whole (as in both clocks). Left hemispatial neglect quite clearly appears in Brenda I.'s daisy, which has petals and leaves only on the right-hand side, and in Sarah M.'s clock, nearly all of whose numbers appear on the right-hand side. Several of the drawings feature unprompted words written by the patient (Brenda I.'s "clock" and "box"). Brenda I.'s drawing of a house is remarkable because of its profound lack of perspective; it fuses into one plane the component parts, such as the roof, the chimney, the path, the side of house, and the floor plan ("Bd" means 'bedroom'). In addition, there is neglect for the left-hand side of the house. All of Brenda I.'s drawings are consistent with the classic description of drawings produced by hearing patients with posterior right-hemisphere lesions. Sarah M.'s drawing, although less impaired than Brenda I.'s, shows severe visuospatial loss in light of Sarah M.'s accomplished artistry before her stroke.

Drawing With a Model

Figure 7.4 reproduces patients' drawings when they were asked to copy the models shown in the left-hand column. As in the preceding test, the drawings by the right-lesioned patients differ considerably from those of the left-lesioned patients. Although these drawings are generally better than those produced without a model, the right-lesioned patients' copies continue to show spatial disorganization, whereas those of the left-lesioned patients do not. Right-lesioned Sarah M. showed only minimal improvement when she had a model to copy (note the elephant and the box). None of the drawings of the left-lesioned patients show evidence of neglect, whereas those of two right-lesioned patients do; for both Sarah M. and Brenda I. significant features on the left-hand side of space (for example, the trunk of the elephant, the arm of the cross, the features on the far left-hand side of Brenda I.'s house) are deleted or distorted. Left hemispatial neglect is especially pronounced in the copies made by Sarah M. All her drawings omit significant features on the left-hand side of space, leaving

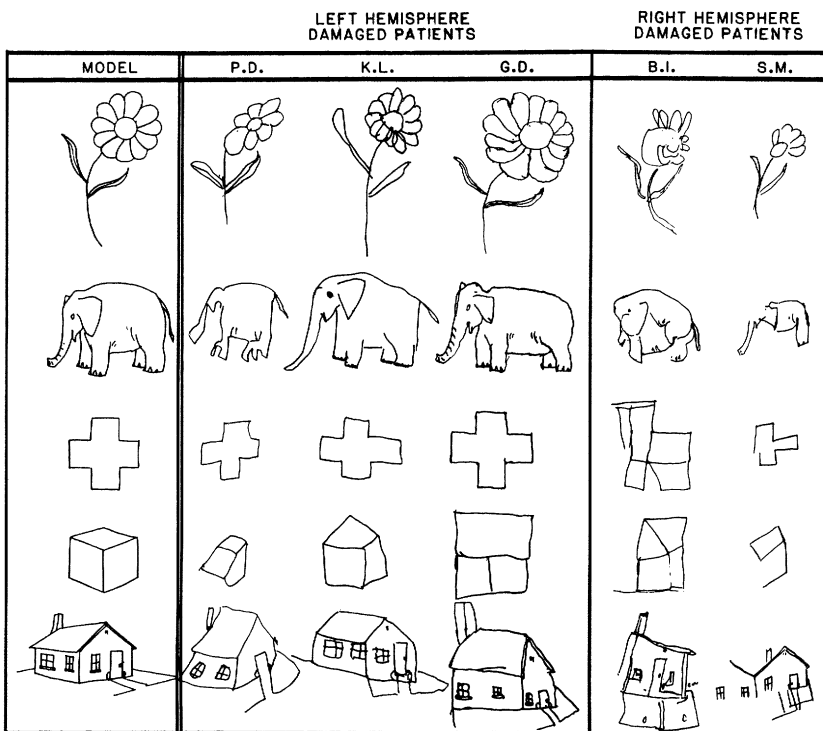


Figure 7.4

Drawing from a model by left- and right-lesioned signers. Note that, even when copying from a model, the right-lesioned signers show spatial distortion, left hemispatial neglect, and failure to indicate perspective.

broken contours (note the elephant, the cross, the box, and the house).

The left-lesioned patients, in contrast, produced fairly good drawings. The distortions in the cross occur only on the right-hand side of space (Paul D. and Karen L.), with the left-hand side of the cross remarkably well preserved. Even Paul D., who had the poorest performance on drawing without a model, does much better with a model to copy. It is interesting that Paul D.'s drawings reveal distortions on the right-hand side (for example, three hind legs on the elephant and the right arm of the cross). The drawings of all three left-lesioned patients now show perspective (the only exception being Gail D.'s box).

The severe spatial disorganization and neglect of the left hemiattentional field of two right-lesioned patients and Brenda I.'s continued

tendency to add unprompted verbal information (for example, “car” to the right of the house) are all features characteristic of hearing patients with posterior lesions to the right hemisphere. The marked superiority of the copied drawings produced by the left-lesioned patients over those of the right-lesioned patients and the fairly well-preserved contours on the drawings by the left-lesioned patients with distortions more prominent in the right hemiattentional field are again consistent with the performance of hearing patients with lesions to the left hemisphere.

Gilbert G.’s drawings are much less distorted than those of the other two right-lesioned patients, as shown in figure 7.5; they are not without distortion, however. In the copy of the cross the arms are elongated and nonsymmetric, and the house shows complete lack of perspective. Despite his reasonably good performance on these drawing tests relative to the other two patients with right-hemisphere damage, we know that Gilbert G.’s ability to do tasks involving visuoconstructive activities was greatly impaired by his stroke. Before his stroke he had been a repair specialist for airplane engines; he also had been a carpenter and had designed and built a patio for his house. As a hobby, he built models and repaired furniture. After his stroke, not only was he unable to continue working in his former capacity, but he also could no longer continue his hobbies or even carry out simple repairs on his home.

Rey-Osterreith Complex Figure

The final drawing task required the patients to copy the Rey-Osterreith complex figure (Osterreith 1944). The model was presented in an upright orientation to four patients (Paul D., Karen L., Sarah M., and Gilbert G.) and in an inverted orientation to the other two patients (Gail D. and Brenda I.). Because the figure is quite complex (figure 7.6), normal subjects usually adopt a number of effective organizational strategies. By far, the most efficient is the drawing of the base rectangle first, then the vertical and horizontal bisectors, followed by the major diagonals. With the figure thus divided into smaller subunits, it is easier to place the internal features in correct relationship to each other. An alternative strategy is simply to divide the base rectangle into four units and then to treat each of the four quadrants separately. The strategies of patients with lateralized lesions not only differ from normal strategies but also show characteristic differences depending on the side of the lesion. In general, hearing patients with damage to the left hemisphere start at the upper left of the figure and draw the contour before filling in (or omitting) internal details. They do not typically draw the base rectangle but tend to

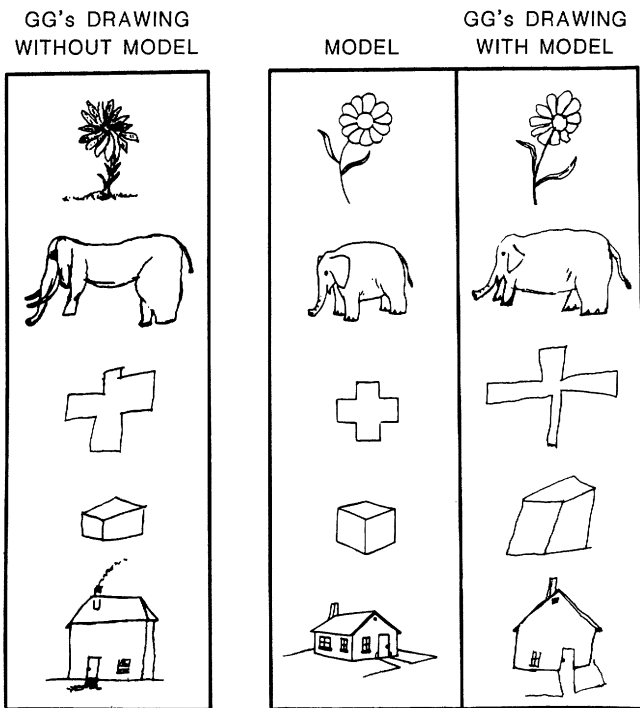


Figure 7.5
Right-lesioned Gilbert G.'s drawings with and without a model. Gilbert G.'s drawings do not show the same degree of impairment as those of the other right-lesioned signers.

track long continuous lines. Their distortions are more prominent on the right-hand side of the figure. Hearing patients with right-hemisphere damage, however, tend to start on the right-hand side of the figure; they typically do not delineate the contour before drawing internal features, and they place component parts in poor spatial relation to each other. Their distortions are more prominent in the left half of the figure (Goodglass and Kaplan 1979).

Of our six patients the three with left lesions produced recognizable copies, whereas two of those with right lesions produced grossly distorted ones. Gilbert G.'s drawing is again much less distorted than those of the other two right-lesioned patients; its overall contour is appropriate, and it shows no neglect. In common with most right-lesioned patients, however, Gilbert G. shows overdrawing of lines, and he extends a series of four parallel lines from the upper left quadrant into the upper right quadrant. Sarah M.'s copy shows massive neglect of left hemispace, with complete omission of the lower

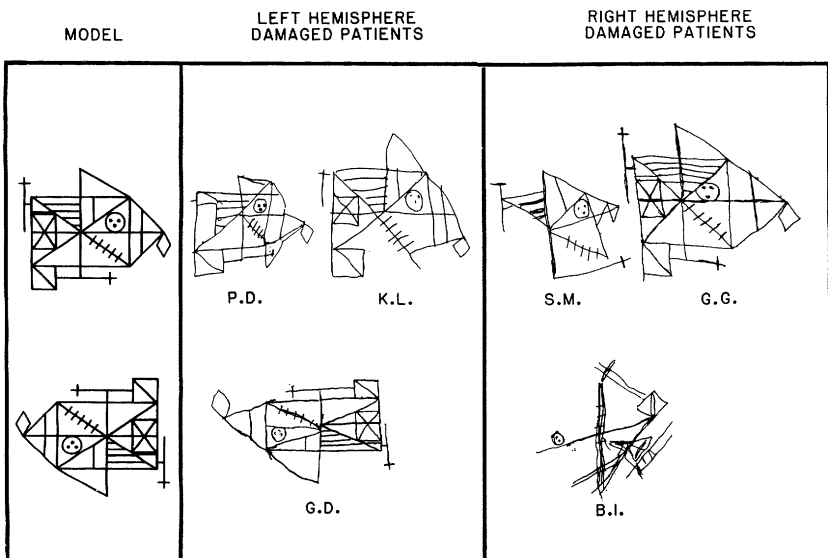


Figure 7.6

Performance in copying the Rey-Osterreith complex figure by left- and right-lesioned signers. The three left-lesioned signers (Paul D., Karen L., and Gail D.) produce recognizable copies, whereas the copies of right-lesioned signers Sarah M. and Brenda I. are grossly distorted.

left quadrant. The broken contour, with parts in incorrect spatial relations, reflects a piecemeal approach without any coherent spatial organization. Brenda I.'s copy is grossly distorted and hardly resembles the model at all. It lacks the overall contour and shows massive left hemispatial neglect and profuse repetition of the same few lines. The few isolated features are drawn in a profoundly segmented fashion. The features that are retained in Brenda I.'s drawing are in poor spatial relationship to one another and are collectively rotated 45 degrees to the right. We scored the copies of the Rey-Osterreith figure according to the criteria set forth by Lezak (1976). Out of a maximum 36 points, the left-lesioned patients scored as follows: Gail D., 31; Karen L., 18; and Paul D., 15. Of the patients with right lesions, Gilbert G. scored 27, and Brenda I. and Sarah M. had extremely low scores of 2 and 8, respectively.

The drawings of the three left-lesioned patients have relatively complete contours, and the features drawn are in relatively good relation to each other. Both left-lesioned Paul D. and Karen L. produced the left-hand side of the rectangle and drew the left-most line of the base rectangle and external square in one continuous line. Left-lesioned Gail D. started at the left-hand side and worked from left to

right. In addition, she tended to organize her drawing into smaller units and then fleshed out the features in each subunit.

Our left-lesioned patients' productions of this complex figure are remarkably similar to the productions of left-lesioned hearing patients. And the contrasting characteristics of the drawings by right-lesioned signers Sarah M. and Brenda I.—the massive left hemispatial neglect and profound spatial disorganization—are virtually indistinguishable from the characteristics of productions by hearing patients with significant large frontoparietal lesions to the right hemisphere.

7.2.2 *Visuoperceptual Task: Facial Recognition*

In hearing individuals it is the right hemisphere that predominantly mediates the recognition of faces (Benton 1980; Rizzolati, Umiltà, and Berlucchi 1971). To assess this capacity in our patients, we administered the Benton et al. (1978) test of facial recognition, which has been standardized by testing a large number of left- and right-lesioned patients and controls. In the first part of the test the patient matches identical front-view photographs. The patient is shown a front-view photograph of a face and is then asked to pick out the identical face from a display of six front-view photographs appearing below it. The patient may identify the target face by pointing to it or by calling out its number. In the second part the patient matches a front-view photograph with three-quarter-view photographs of the same face. The person shown in front-view in the target photograph appears three times in the three-quarter-views in the display of six (figure 7.7). The patient picks out the three faces that match the target one. In the third part a single front-view photograph must be located three times in a display of six front-view photographs taken under different lighting conditions.

Benton et al. (1983) provide normative data on control subjects and on brain-damaged patients, with corrections for age and educational level. They found that hearing patients with right-hemisphere damage performed substantially worse than patients with left-hemisphere damage. Scores ranging from 41 to 54 are considered normal; 39 and 40, borderline; 37 and 38, defective; and 0 to 36, severely defective. The left-lesioned patients in our study scored as follows: Paul D., 47; Karen L., 41; and Gail D., 47. Of the right-lesioned patients, Brenda I. scored 38, and both Gilbert G. and Sarah M. scored 43. The three left-lesioned patients and two of the right-lesioned patients performed well within the normal range; one right-lesioned patient, Brenda I., showed defective performance.

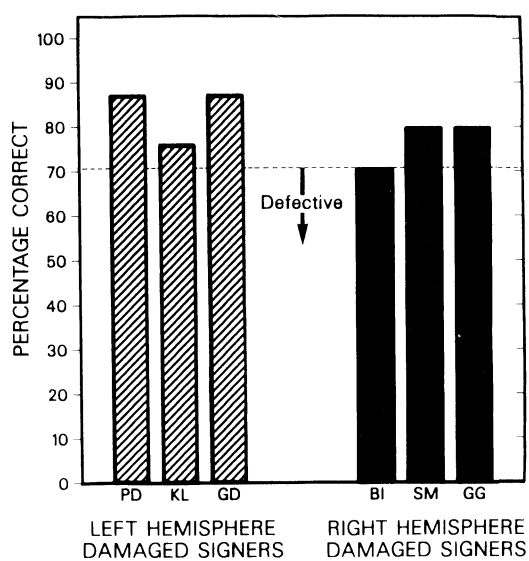
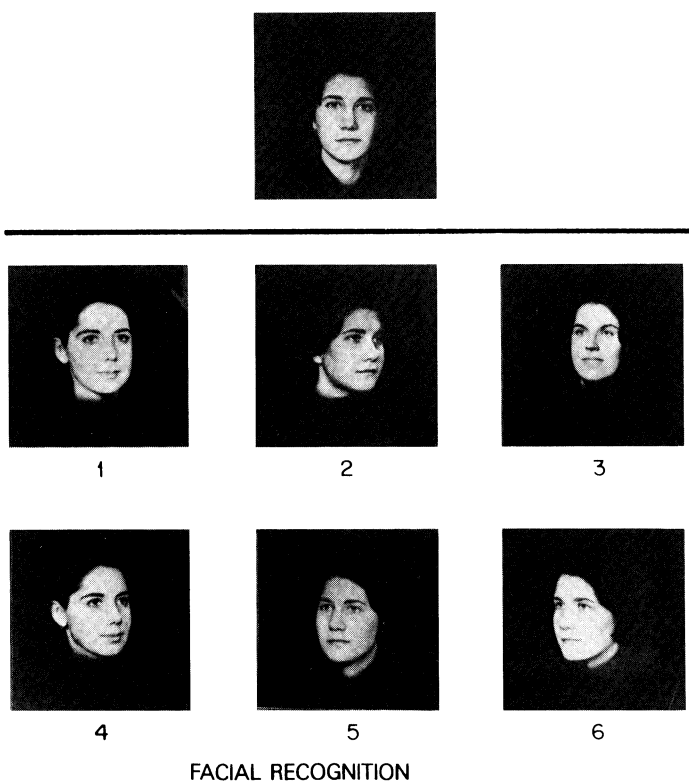


Figure 7.7
Performance on the Benton et al. Test of Facial Recognition by left- and right-lesioned signers.

7.2.3 Visuospatial Tasks

Unilateral Neglect

We administered two tests for unilateral visual neglect. The left-lesioned patients Paul D. and Karen L. were asked to mark the mid-points of a series of horizontal lines of different lengths. Patients with unilateral neglect tend to put the mark off center, away from the neglected side, as if they were bisecting only the portion of the line that they do not neglect (Benton 1979). Patients with unilateral lesions who do not show neglect tend to show slight displacements toward the side of their lesion. Neither Paul D. nor Karen L. substantially displaced their marks from center; their bisections were, however, all displaced slightly to the left of center (averaging 3.1 percent and 5.3 percent, respectively). There was no evidence of neglect in these left-lesioned signers, which is consistent with their performance on the visuospatial tests previously discussed.

All the patients except Paul D. also took a test of unilateral visual neglect (see Albert 1973). In this test patients cross out forty lines that are arranged pseudorandomly on a page (figure 7.8). Albert (1973) reports that control subjects (subjects with no brain damage) cross out every line but that patients with neglect cross out fewer lines in the neglected half of the page than in the other half. The performance of the five signers, two left-lesioned and three right-lesioned, are shown

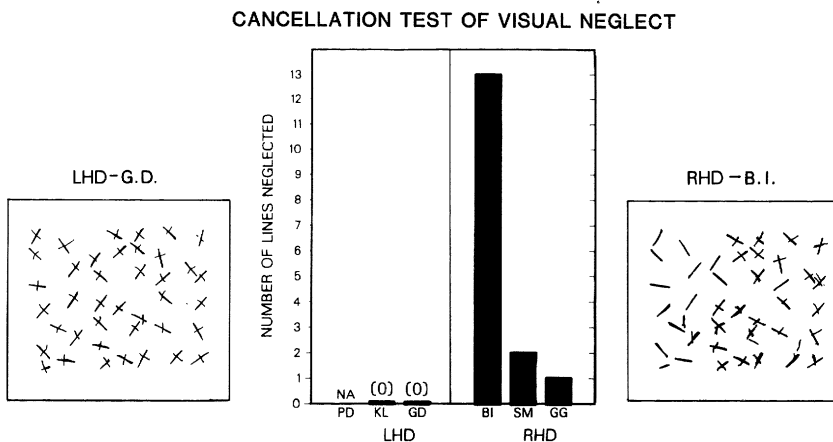


Figure 7.8

Performance on a test of unilateral visual neglect by left- and right-lesioned signers. The contrast between performance of a left- and a right-lesioned signer is presented. All right-lesioned signers showed evidence of neglect.

in figure 7.8. The two left-lesioned patients, Gail D. and Karen L., showed absolutely no evidence of neglect; they crossed out every line. In contrast, all of the right-lesioned signers showed left hemispatial neglect. Sarah M. and Gilbert G. showed mild neglect, failing to cross out two and one lines, respectively, all on the left-hand side. Brenda I. showed massive left neglect. She failed to cross out one line on the right, missed none in the center, but failed to cross out *thirteen* lines on the left. Although Sarah M. showed only mild left neglect on this test, she exhibited strong left neglect in her drawings. These results are also consistent with the performance of hearing patients with lateralized lesions.

Judgment of Line Orientation

In hearing persons it is primarily the right hemisphere that mediates the perceptual capacity to judge the spatial orientation of lines. As with facial recognition, the superiority of the right hemisphere for this processing has been demonstrated in experimental studies of normal subjects and in studies of brain-damaged patients (Fontenot and Benton 1972; Benton, Hannay, and Varney 1975). To assess this capacity in our patients, we used the Benton, Varney, and deS Hamsher (1977) test of judgment of line orientation. This test has been standardized by testing a large number of brain-damaged and control subjects (Benton et al. 1983). The subject is required to match the angular orientation of two simultaneously presented lines to a response-choice display of eleven lines. Each of the five practice items consists of a pair of lines from the response-choice display that are shown in full length. Each of the thirty test items consists of a pair of lines of partial length. Each partial line corresponds to the orientation of one of the lines appearing in the response-choice display below it. The partial lines represent the upper, middle, or lower segments of the response-choice lines. The subject responds by pointing to or giving the numbers of the appropriate response-choice lines. Score corrections are provided for age level and sex of the subject.

Benton et al. (1983) classify scores based on percentile rankings of control subjects. Scores from 21 to 30 range from average to superior; scores from zero to 20 range from severely defective to borderline. It is interesting that left-lesioned Paul D. obtained a score of 13 (and on a retest a score of 12). These scores fall in the severely defective range. Karen L. obtained a score of 17, which is classified as moderately defective. Gail D. scored 24, which is classified as average. With respect to the right-lesioned patients, Brenda I. obtained a score of 5, which is classified as severely defective, and Sarah M. scored 20, which is borderline. It is also interesting that Gilbert G. was severely

impaired on this task, receiving a score of only 12, thus showing severe impairment on this spatial task of matching and extrapolating the angular orientation of lines. In general, the right-lesioned patients performed worse on this task than the left-lesioned patients (although Paul D., left-lesioned, is defective). This task taps certain spatial cognitive capacities that may also serve as prerequisites to ASL grammar, because the task depends heavily on spatial distinction and spatial location (for example, in the pronominal and verb agreement systems).

7.3 *Capacities across Right- and Left-lesioned Signers*

The data presented here suggest that the effects of lesions in the left or right hemisphere of deaf signers are similar to the effects in hearing individuals for the processing of visuospatial information. In fact, the behavior of a patient with damage to one hemisphere may be viewed not as the impaired performance of a damaged hemisphere but rather as a manifestation of the functioning of the relatively intact hemisphere (Goodglass and Kaplan 1979). The three deaf patients with left-hemisphere damage tended, in general, to process spatial relationships appropriately; this reflects the functioning of their intact right hemisphere. The deaf patients with damage to the right hemisphere, however, showed, in general, the classic visuospatial impairments seen in hearing patients with right-hemisphere damage.

The WAIS-R Block Design Test provides an important assessment of visuospatial capacity. The deaf patients generally performed in a manner similar to hearing patients. The left-lesioned deaf patients had difficulty with the right-hand side of the designs and did not break the external configurations of the designs. In contrast, all three right-lesioned patients broke the external configurations of designs.

In drawing with and without a model, the left-lesioned patients generally drew the contour or configuration but tended to simplify and omit details. In sharp contrast, two of the right-lesioned patients grossly distorted the spatial relations of component parts but nonetheless included many internal details. (The third right-lesioned patient, Gilbert G., was less impaired in these drawing tasks.) Furthermore, consistent with the results from hearing patients, left-lesioned patients' copies of a model were much improved over their drawings without a model; indeed, perspective was indicated as well. The right-lesioned patients, however, were unable to indicate perspective, and the addition of the model did not substantially improve the performance of one right-lesioned patient (Sarah M.). In addition,

Sarah M.'s poor performance is remarkable, because she was an accomplished painter before her stroke. Clearly, her right-hemisphere damage produced a serious spatial loss.

One of the left-lesioned patients, Paul D., performed somewhat differently from the other two. His drawings from memory were extremely simplified and showed some bilateral distortion. Indeed, Paul D.'s performance across the array of tests was the most severely impaired of the three left-lesioned patients. A generalized visuospatial loss often occurs in elderly subjects, brain damaged or not. Paul D. is 81; thus in his case the effects of age and of brain damage may be confounded. (In fact, we plan to pursue the possibility that loss of visuospatial capacities with age might impair certain aspects of sign comprehension and production.) The performance of the six patients in copying the Rey-Osterreith complex figure also parallels that of hearing patients with unilateral brain damage. Again, the right-lesioned patients distorted spatial relations, showing massive left hemispatial neglect and overwriting of lines. On the other hand, the three left-lesioned patients drew fairly accurate configurations and proceeded with the task in a manner similar to hearing patients with left-hemisphere damage.

Another parallel between the performances of deaf and hearing patients comes from an evaluation of unilateral visual neglect. As is generally true of hearing patients, the left-lesioned signers showed no unilateral neglect, whereas the right-lesioned signers did. We also note that, clinically, the only deaf patient unable to find her way about a familiar environment was the right-lesioned patient Brenda I. She had difficulty locating her own room and that of a deaf friend in a nursing home where they both had lived for several years. Again, consistent with hearing patients, none of the left-lesioned patients showed this topographic disorientation.

Concerning the recognition of unfamiliar faces, the left-lesioned patients performed normally, whereas one right-lesioned patient (Brenda I.) was defective and the other two scored within the normal range. On another test of right-hemisphere ability, judgment of line orientation, the right-lesioned signers performed poorly. Two of the three right-lesioned signers were severely defective, consistent with the performance of hearing patients with right-hemisphere damage. It is interesting to note that right-lesioned Gilbert G., who showed less impairment in drawing than the other right-lesioned patients, was severely defective in the perception of this spatial task.

In summary, the overwhelming weight of evidence from this study indicates that deaf signers show hemispheric specialization for non-language visuospatial processing that is similar in almost all respects

to that of hearing speakers. We confirmed this with tests that have been shown to differentiate clearly between the performances of left-lesioned and right-lesioned hearing subjects. What are the implications of these data for hemispheric specialization? First, it seems clear that auditory experience is not necessary for the development of hemispheric specialization. Three of our patients were congenitally deaf (Gail D., Brenda I., and Sarah M.); one has been deaf since the age of 6 months (Karen L.). Only two became deaf postlingually (Paul D. and Gilbert G.); only they could have developed hemispheric specialization based on hearing and speech before deafness. Yet all the deaf patients clearly show hemispheric specialization. Indeed, the congenitally deaf patients are exactly the ones whose performance most clearly mirrors the classic differences in visuospatial functioning that have been found between hearing left-lesioned and right-lesioned patients.

This excerpt from

What the Hands Reveal About the Brain.
Howard Poizner, Edward Klima and Ursula Bellugi.
© 1990 The MIT Press.

is provided in screen-viewable form for personal use only by members of MIT CogNet.

Unauthorized use or dissemination of this information is expressly forbidden.

If you have any questions about this material, please contact
cognetadmin@cognet.mit.edu.