

CHAPTER 3

The signs of aphasia

Gregory Hickok ^a and Ursula Bellugi ^b

^a Department of Cognitive Sciences, University of California, Irvine, CA 92697, USA

^b Laboratory for Cognitive Neuroscience, The Salk Institute for Biological Studies, 10010 N. Torrey Pines Rd., La Jolla, CA 92037, USA

Introduction to language in another modality

Theoretical issues

Much debate in 19th century neurology centered around the question of whether there is functional specialization within the neocortex. Today, this is no longer a contentious issue: functional specialization in the adult neocortex is well established. Nonetheless, a form of this old debate rages on in research on neocortical development. At issue is whether neocortical regionalization arises from properties intrinsic to the neocortex itself (Rakic, 1988), or whether it develops in response to extrinsic factors, such as patterns of thalamocortical input (O'Leary, 1989). Over the last decade, evidence has accumulated on both sides of the fence. Many studies, for example, have demonstrated a fair degree of neocortical reorganization in response to a variety of sensory-input manipulations (Katz and Shatz, 1996; Pons, Garraghty, Ommaya et al., 1991; Sadato, Pascual-Leone, Grafman et al., 1996; Schlaggar and O'Leary, 1991; Sur, Garraghty and Roe, 1988), suggesting that extrinsic factors exert an influence on neocortical organization. Other studies, however, have shown that some regional specific features of neocortex (e.g. gene expression) emerge independent of extra-neocortical influence (Afimatsu, Miyamoto, Nihonmatsu et al., 1992; Miyashita-Lin, Hevner, Wassarman et al., 1999). Taken together, this collection of work seems

to suggest that there are both intrinsic and extrinsic influences driving neocortical organization (Nothias, Fishell and Ruiz i Altaba, 1998). If this view is correct, a major task in developmental neuroscience will be to map out the contributions of intrinsic and extrinsic factors, and their interaction.

In this chapter, we will present data which bear on these general issues from the perspective of the organization of a higher-order cortical system: language. In particular, we will address the question of the extent to which the functional neuroanatomy of language is dependent on the sensory and motor modalities through which it is perceived and produced. There are many reasons to think that the neural organization of language should be profoundly influenced by extrinsic factors in development, such as sensory and motor experience. The temporal processing demands imposed by the auditory system have been argued to favor left hemisphere systems which could, in turn, determine aspects of the lateralization pattern of auditory-mediated language (Tallal, Miller and Fitch, 1993). Superior temporal lobe regions thought to be important for language comprehension are situated in and around auditory cortices - a natural location given auditory sensory input of language. Likewise, Broca's area, which is thought to play a role in speech production, is situated just anterior to motor cortex controlling the speech articulators. Thus, it would not be unreasonable to hypothesize that the neural organization of language - including its lateralization and within-hemisphere organization - is determined, in large part, by the particular demands imposed by the sensory and motor interface systems.

*Corresponding author. Tel.: + 1 (858) 453-4100, ext. 1222.

By studying the functional neuroanatomy of signed language, we can test this hypothesis in a straightforward manner. It has been shown that signed languages share a good deal of the formal linguistic structure found in spoken languages, but differ radically in the sensory and motor systems through which language is transmitted (Klima and Bellugi, 1979; Lillo-Martin, 1991; Perlmutter, 1992). In essence, signed language offers a kind of natural experimental manipulation: central linguistic structure and function are held constant, while peripheral sensory and motor experience is varied. Thus, a comparison of the neural organization of signed versus spoken language will provide clues concerning the factors which drive the development of the functional neuroanatomy of language.

The structure of sign language

Like spoken languages, signed languages of the deaf are formal, highly structured linguistic systems, passed down from one generation to the next, with a typical developmental course, including a critical period for acquisition (Newport and Meier, 1985; Newport, 1991). Signed languages have emerged independently of the language used among hearing individuals in the surrounding community: American Sign Language (ASL) and British Sign Language, for example, are mutually incomprehensible, despite the fact that English is the dominant spoken language in both surrounding communities.

Signed and spoken languages, however, share the underlying structural complexities of human language. That is, all natural human languages have linguistic structure at phonological, morphological, and syntactic levels, and signed languages are no exception. At the phonological level, research has shown that like the words of spoken languages, signs are fractionated into sublexical elements, including various recurring handshapes, articulation locations, and limb/hand movements, among other features (Corina and Sandler, 1993; Perlmutter, 1992). Furthermore, comparison of two different signed languages (ASL and Chinese Sign Language) reveals that there are even fine-level systematic phonetic differences leading to an 'accent' when native users of one sign language learn another (Klima and Bellugi, 1979; Poizner, Klima and Bellugi, 1987). At the morpholog-

ical level, ASL, for example, has developed grammatical markers that serve as inflectional and derivational morphemes; these are regular changes in form across classes of lexical items associated with systematic changes in meaning (Klima and Bellugi, 1979). At the syntactic level, ASL specifies relations among signs using a variety of mechanisms including sign order, the manipulation of sign forms (usually verbs) in space, where different spatial relations between signs have systematic differences in meaning, and a specific set of grammaticized facial expressions that are used to mark questions, topicalized sentences, and conditionals (Liddell, 1980; Lillo-Martin, 1991). Fig. 1 shows aspects of the spatial organization of ASL at (A) the lexical level, (B) the morphological level, and (C) the level of spatially organized syntax.

In summary, ASL has developed as a fully autonomous language with grammatical structuring at the same levels as spoken language and with similar kinds of organizational principles. Yet the surface form that this grammatical structuring assumes in a visual-spatial language is deeply rooted in the modality in which the language developed in that there is a strong tendency to encode grammatical relations spatially rather than temporally. The implication of this situation for research on the neurobiology of language is that we have the opportunity to study a linguistic system that is essentially identical to that of spoken language in terms of its underlying linguistic (i.e. representational) structure, but that is implemented in a radically different perceptual signal.

Brain organization for language and spatial cognition in deaf signers

Hemispheric asymmetries for aspects of sign language

Left hemisphere damage in hearing/speaking individuals is associated with deficits at sublexical ('phonetic/phonemic'), lexical, and sentence levels, both in production and in comprehension (Damasio, 1992; Goodglass, 1993). Supra-sentential (e.g. discourse) deficits, on the other hand, have been associated with right-hemisphere damage (Brownell, Potter, Bihrlé et al., 1986). A similar pattern of hemispheric asymmetries has been observed in the deaf signing population.

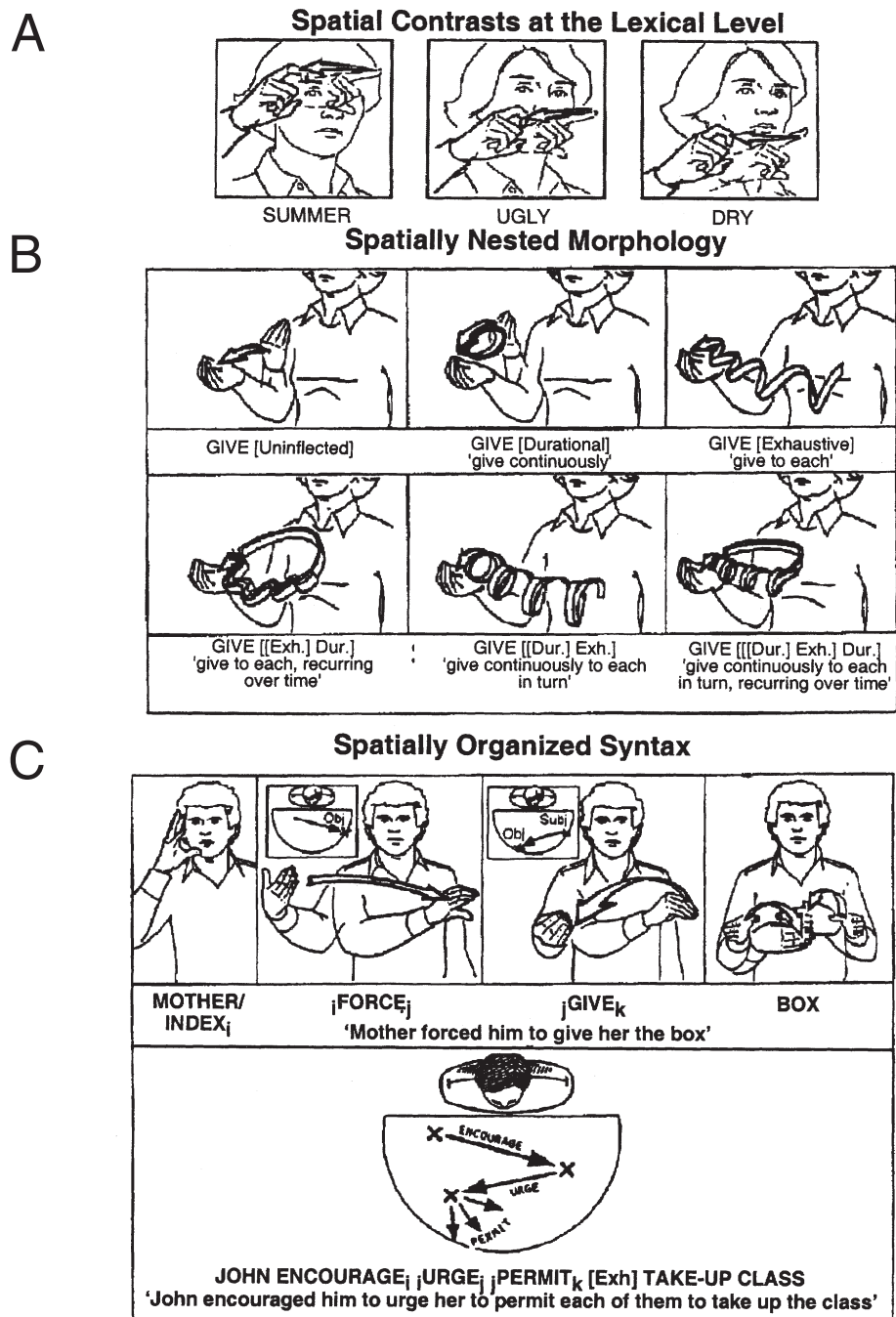


Fig. 1. Spatialized linguistic contrasts in ASL structure. (A) Spatial contrasts at the lexical level. The signs for SUMMER, UGLY and DRY, are distinguished only by the place of articulation on the face. (B) Spatial contrasts at the morphological level. Various modulations on the movement of the sign GIVE, for example, can modify the meaning of the verb as indicated. The modulations can be nested to yield complex morphological forms. (C) Spatialized organization underlying the syntax of ASL. Signs can be indexed to specific locations in signing space, and the direction of movement of the verb between spatial endpoints indicate grammatical relations, such as subject and object.

Sublexical-, lexical-, and sentence-level processes

A variety of sublexical-, lexical-, and sentence-level deficits (i.e. typical aphasic symptomology) have been found in individual left-hemisphere-damaged (LHD) deaf signers (Bellugi, Poizner and Klima, 1989; Corina, 1998; Hickok, Bellugi and Klima, 1998a; Hickok, Klima and Bellugi, 1996a; Hickok, Klima, Kritchevsky et al., 1995b; Kimura, 1981). These deficits have been noted both in production, and in comprehension. In production, a range of paraphasic error types have been identified in LHD signers, including 'phonemic', morphological, and semantic subtypes, demonstrating the breakdown of these various levels of computation (Hickok et al., 1998a; Poizner et al., 1987). Some examples of phonemic and paragrammatic paraphasias are provided in Fig. 2. Note that phonemic errors have been identified involving the range of sign-phonologic features including hand-shape, location, movement, and orientation. Disorders in sign language sentence formation in LHD signers have emerged both in the form of agrammatism (production of grammatically impoverished utterances) and in the form of para-grammatism (production of grammatically rich, but disordered utterances), showing that sign sentence level computations can also be disrupted following LHD in deaf signers (Hickok et al., 1998a; Poizner et al., 1987). Production errors at all these levels are fairly common in LHD signers, but occur very rarely, if at all, in right-hemisphere-damaged (RHD) signers (Hickok et al., 1996a). On the comprehension side, we have documented deficits at the word (i.e. sign) and sentence level (Hickok et al., 1996a), observed only following LHD, not RHD. At the sentence level, LHD signers also perform significantly worse than do RHD signers.

To confirm the hypotheses suggested by case studies that the left hemisphere is dominant for sublexical-, lexical-, and sentence-level processes in sign language, we have carried out a group study comparing 13 LHD and 10 RHD signers on a range of standard language tests (Hickok et al., 1996a). Using our ASL-adapted version of the Boston Diagnostic Aphasia Examination (BDAE) (Goodglass and Kaplan, 1983), we assessed each subject's competence in several basic aspects of language use: production, comprehension, naming, and repetition. Production measures included

the BDAE ratings of signing characteristics, as well as a count of the number of paraphasic errors per minute of signing. Comprehension measures included a set of one-, two-, and three-step commands (BDAE 'Commands' subtest) and an ASL-adapted version of the Token Test (DeRenzi and Vignolo, 1962). Naming assessment included two BDAE subtests: Visual Confrontation Naming (naming in response to pictures) and Responsive Naming (naming in response to questions; e.g. "What do you do with a book?"). Repetition ability was assessed using the BDAE Phrase Repetition subtest. A subset of subjects (10 LHD, 7 RHD) also took a 'rhyme' judgment test in which they were asked to choose (out of an array of four) the two pictured objects whose signs 'were most similar in terms of the number of sign-phonological features. LHD signers performed significantly worse than RHD signers on all measures (Fig. 3). The differences hold up even if subjects with lesions outside the perisylvian region are excluded, thus correcting for possible sampling bias in the distribution of lesions, and when only native deaf signers are included in the analysis. Finally, the difference between LHD and RHD signers is not a function of sampling error due to group differences in (1) age at test, (2) onset of deafness, or (3) age of exposure to ASL; collapsing across the two groups, there is no correlation between the total score on the full BDAE rating scales (comprehension scale included) and these three variables ($P = 0.99, 0.52, \text{ and } 0.91$, respectively). This is not to say that these variables have no impact on sign language organization or language ability, because surely they do at some level of detail, only that the dominant factor which predicts performance on these within-sentence linguistic tests is whether the left or right hemisphere is damaged.

Supra-sentential (discourse) deficits

One linguistic deficit which has been associated with right hemisphere damage in hearing/speaking individuals involves extra-grammatical and discourse level processes, that is, the ability to link appropriately (in production and comprehension) discourse referents across multiple sentences (Brownell et al., 1986; Wapner, Hamby and Gardner, 1981). These deficits manifest as failures to integrate information across sentences, including impairments in understanding

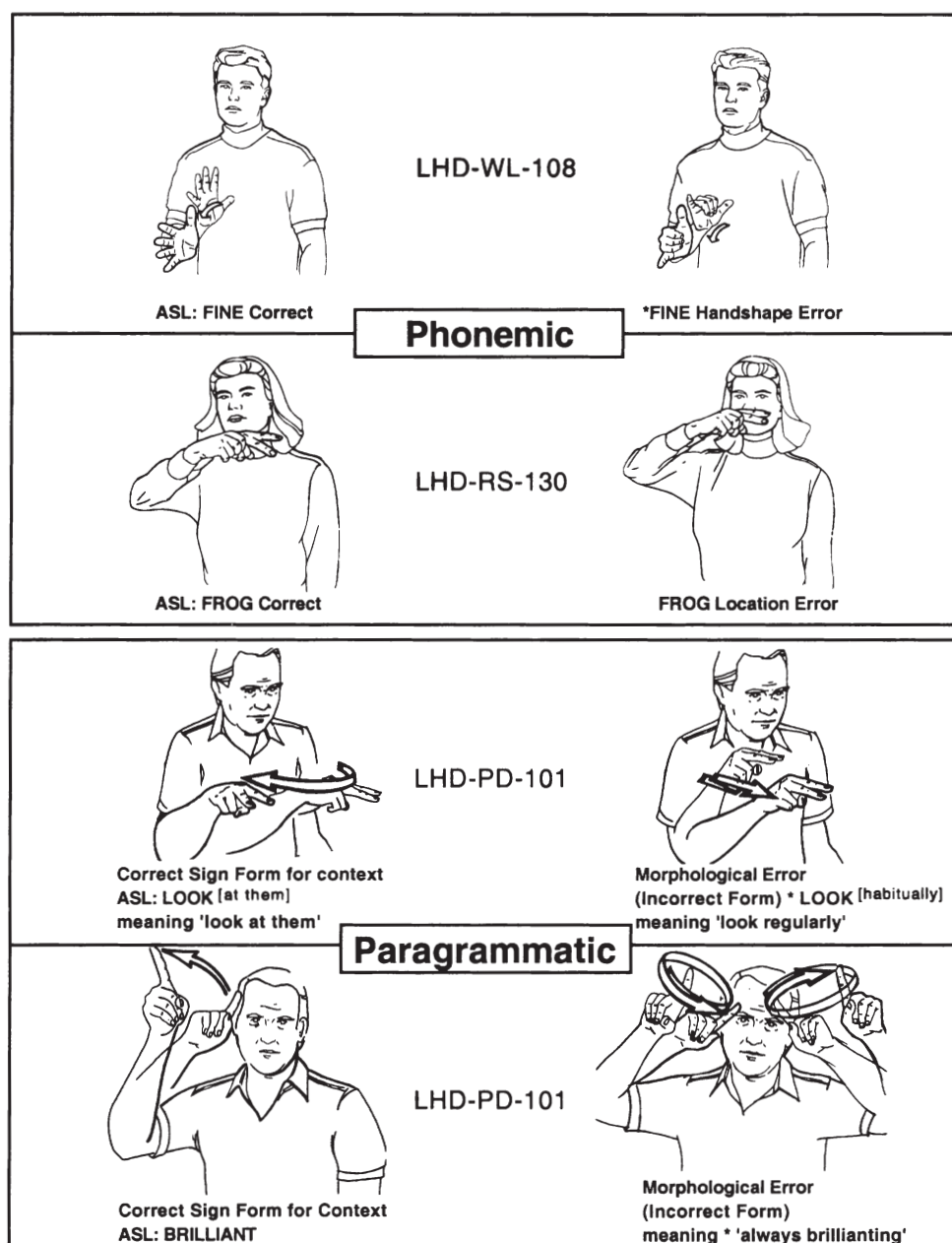


Fig. 2. Phonemic and paragrammatic errors in LHD deaf signers. Phonemic errors based on substitution of sublexical components of ASL (e.g. handshape and location). Paragrammatic errors based on substitution of one grammatical inflection for another, or an overextension of a grammatical inflection.

jokes, in making inferences, and in adhering to the story-line when producing a narrative. In contrast, phonological and syntactic processes in these hearing/speaking individuals appear to be intact. Informal observation of some RHD deaf signers, suggested that, although right hemisphere damage does not

cause aphasia, it may impair discourse functions in ASL, just as it does in spoken language. More formal observations using a story narration task given to two deaf RHD signers, have revealed at least two distinct types of discourse deficits (Hickok, Wilson, Clark et al., 1999). The first involves a failure to adhere to the

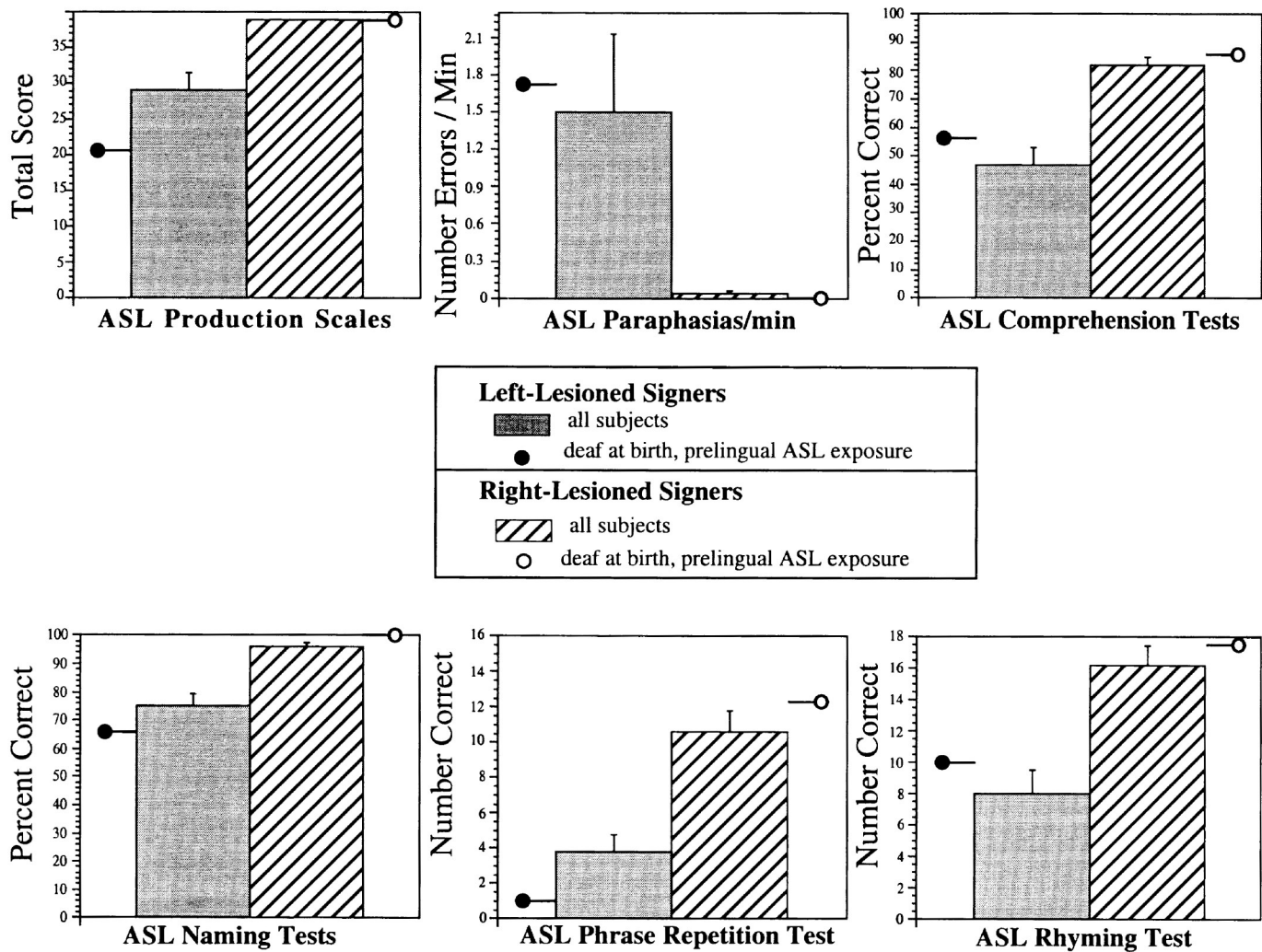


Fig. 3. LHD deaf signers' impairments in language functions. Graphs provide means and standard error bars for LHD ($n = 13$) versus RHD ($n = 10$) signers on six measures of ASL ability. Circles indicate level of performance among the subset of this study population who were prelingually deaf native signers (LHD, $n = 4$; RHD, $n = 3$). Production Scales, sum score on our ASL-adapted version of the BDAE; Paraphasias/min, total number of sign errors in a sign sample elicited according to BDAE protocol; Comprehension Tests, BDAE commands subtest and our ASL-adapted version of the Token Test (DeRenzi and Vignolo, 1962); Naming Tests, BDAE visual confrontation and responsive naming tests; Phrase Repetition Test, ASL version of the BDAE Phrase Repetition test; Rhyming Test, a 'rhyme' judgment test in which subjects choose (out of an array of four) the two pictured objects whose signs were most similar in terms of sign-phonological features (Poizner et al., 1987); $n = 10$ LHD and $n = 7$ RHD.

story-line, evidenced most often with confabulatory or tangential utterances, both of which have been discussed in relation to hearing/speaking RHD patients. The second type of deficit involves errors in the use of the spatialized discourse of ASL.

Discourse organization in ASL is unique in that discourse referents are established, referred to, and of correct spatial discourse organization in a storytelling task, including shifts in the referential signing space,

and also shows the errors made by an RHD signer. We tabulated the ratio of confabulatory or tangential utterances in each patient as well as the number of errors in each patient's spatially organized discourse. The results are as follows. Case RHD-221-AR made only one spatial discourse error, but 60% of his utterances were confabulatory/tangential. Case RHD-216-SJ showed the reverse pattern. He confabulatory/tangential utterances (see Fig. 413). A

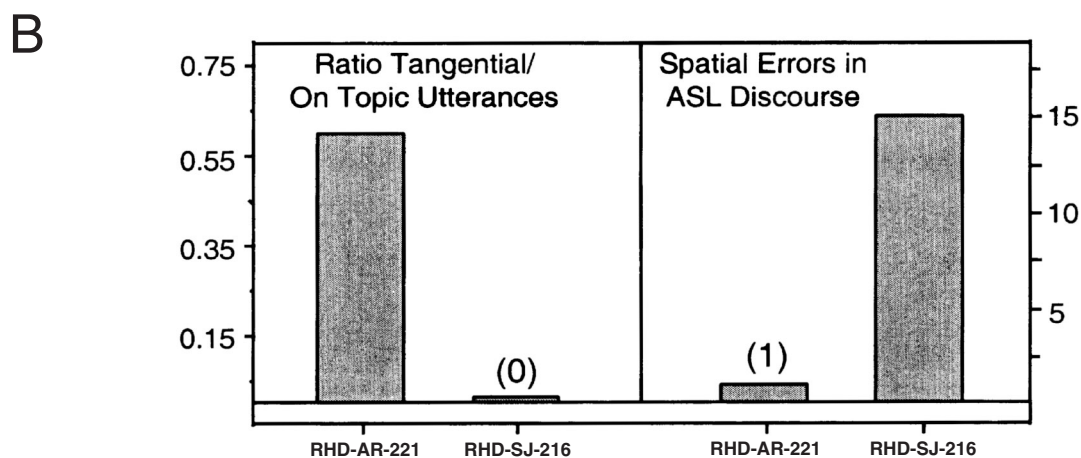
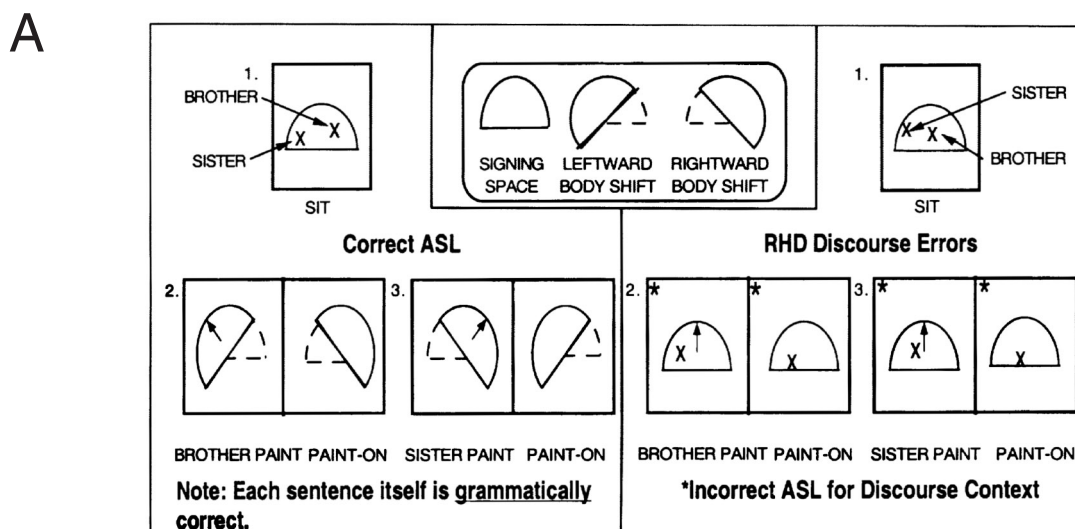


Fig. 4. Discourse deficits in RHD signers. (A) An example of spatialized discourse errors in an RHD signer. (13) Performance of two RHD signers on two measures of discourse function.

spatialized discourse deficit has also been observed in RHD-207-DN, a hearing signer (Clark, Hickok, Batch et al., 1995; Poizner and Kegl, 1993). These results suggest: (1) the right hemisphere is involved in discourse processing in ASL, as it is in spoken language; and (2) there are dissociable subcomponents of discourse processes in ASL that are unique to its spatial linguistic organization.

Hemispheric asymmetries for spatial cognition

The previous section presented evidence which suggests that the lateralization pattern of sign language systems is similar to that of spoken language. Here

we present evidence suggesting that the lateralization pattern of non-linguistic spatial functions is also very similar between deaf and hearing individuals.

Gross visuospatial deficits in RHD signers

RHD in hearing speaking individuals often leads to substantial visuospatial deficits which are evidenced, in the most severe cases, by grossly distorted productions in, for example, drawing tasks and block arrangement tasks (Kirk and Kertesz, 1994). In contrast to the LHD signers, several of the RHD signers in our study population presented with similar kinds of gross visuospatial deficits (see Fig. 5). The left column illustrates the relatively preserved spatial abil-

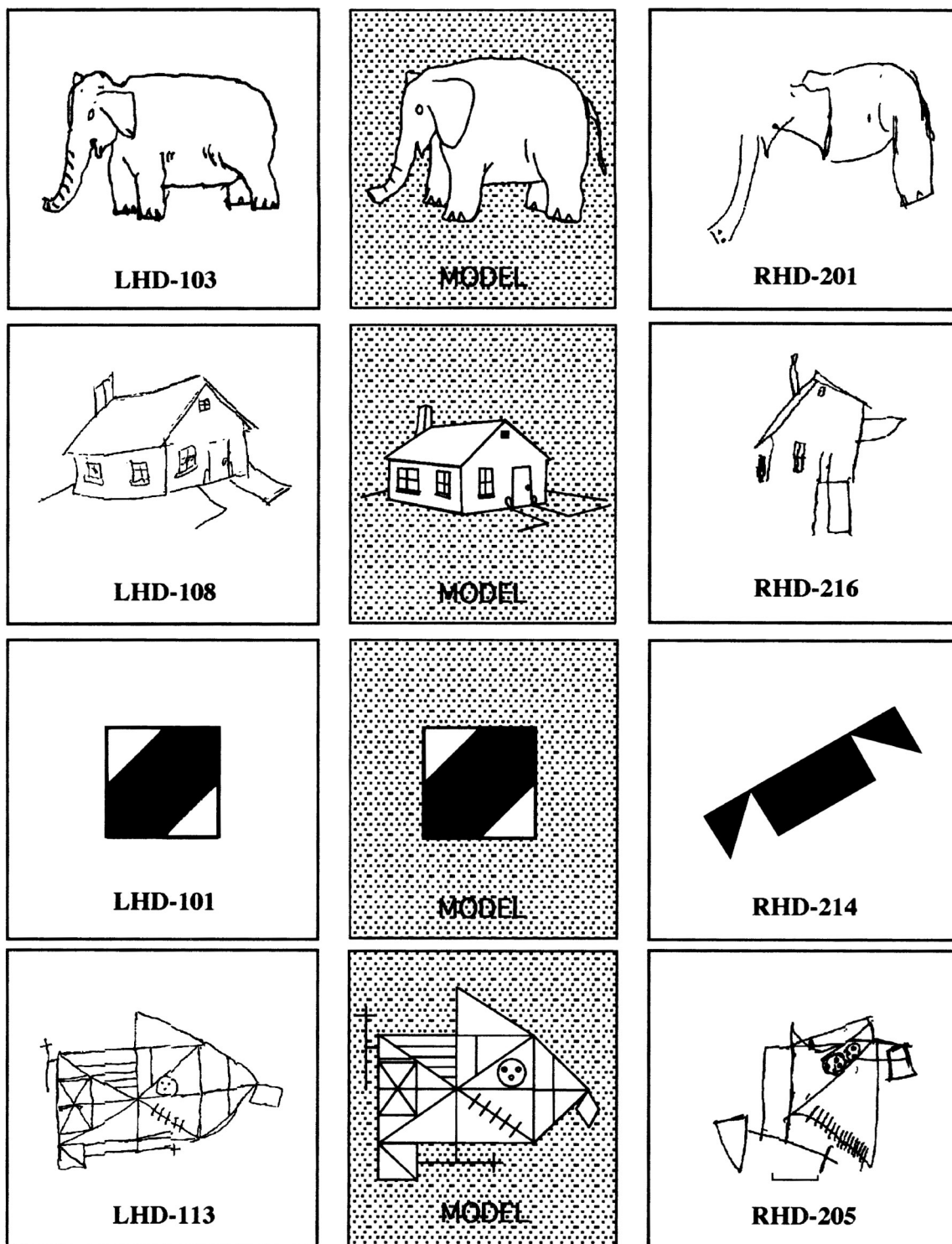


Fig. 5. RHD deaf signers show impairment in non-language visuospatial functions. The LHD signers (left column) showed relatively preserved non-language functions as shown by their drawings and block design, whereas the RHD signers (right column) showed many impairments in non-language visuospatial functions. Note the left neglect, the lack of perspective, and the disorganization in block design and drawings for RHD signers.

ities of LHD deaf signers. The middle column illustrates the models used for drawing and block design in spatial tasks. The right column illustrates the impaired performance of RHD signers, including neglect of the left side of space, lack of perspective, and disorganized drawing or block design. Despite sometimes severe non-linguistic visuospatial impairments, none of the RHD signers had aphasia.

Local/global differences

While gross visuospatial deficits may more commonly occur with RHD (both in deaf and hearing populations), it has been reported that some visuospatial deficits can be reliably observed in LHD hearing individuals (Delis, Kiefner and Fridlund, 1988; Kirk and Kertesz, 1994). When LHD individuals have visuospatial deficits, they typically involve difficulties in attending to and/or reproducing the local-level details of a visuospatial stimulus, while global-configuration aspects are correctly identified/reproduced. RHD hearing individuals tend to show the opposite pattern. Thus, it has been suggested that the left hemisphere is important for local-level visuospatial processes, whereas the right hemisphere is important for global-level processes (Delis et al., 1988). We investigated whether a similar asymmetry would be observed in our deaf study population (Hickok, Kirk and Bellugi, 1998c). A group of left or right lesioned deaf signers were asked to reproduce (1) two line drawings (a house and an elephant), and (2) four hierarchical figures (e.g. the letter 'D' composed of small 'Y's). Drawings were scored separately for the presence of local vs. global features. Consistent with data from hearing patients, the LHD deaf subjects were significantly better at reproducing global-level features, whereas the RHD deaf subjects were significantly better at reproducing local-level features. This effect held for both types of stimuli.

Hemispatial neglect issues

Left hemispatial neglect is a symptom that is strongly associated with RHD in the hearing population (Heilman, Watson and Valenstein, 1997). We have noticed a similar association in our deaf study population (Poizner et al., 1987). Several of the RHD signers presented with significant symptoms of left hemispatial neglect which showed up in drawing tasks, in line

cancellation tasks, and in line bisection tasks. Perhaps surprisingly, even severe hemispatial neglect does not seem to interfere substantially with normal sign language communication, either in terms of production or comprehension (Corina, Kritchevsky and Bellugi, 1996) (see Fig. 6), except when the patient is asked to communicate information about spatial relations, such as describing the layout of a room (Poizner et al., 1987). In one case, for example, a patient with left hemispatial neglect described the layout of furniture in her room using grammatically correct utterances and correctly enumerating all the objects; however, the position of the furniture within the room was incorrectly described, with most of the items 'piled up' on the right side of space, neglecting the left side, and yet her signing was impeccable otherwise. We have not seen hemispatial neglect in LHD signers in our study population.


To the extent studied thus far, hemispheric asymmetries for language and spatial cognition in deaf lifelong signers is indistinguishable from those found in the hearing/ speaking population.

Within-hemisphere organization for sign language

Functional aspects: syndromes and symptoms

To the extent that the types and patterns of deficits found in aphasia for sign language are similar to what is found in aphasia for spoken language, it suggests a common functional organization between the two forms of language. There do seem to be a great number of commonalities in the language deficits found in signed versus spoken language: many of the aphasic symptom clusters we have observed in our LHD signers fall within the bounds of classical clinical categories defined on the basis of hearing aphasics (Goodglass and Kaplan, 1983), and the lesions producing these patterns of deficits in LHD signers are consistent with clinical-anatomic correlations in the hearing population (Damasio, 1992). Examples of this include the following observations: (1) we have not identified a case in which a lesion outside the perisylvian language zone has led to a primary aphasia (although, admittedly, we have not seen a wide range of patients with extra-perisylvian lesions); (2) non-fluent aphasic signers have lesions involving anterior language regions; and (3) fluent aphasic signers have

Omission of Left Space in Drawing



Syntactic Agreement Using Left Space in RHD-JH-205

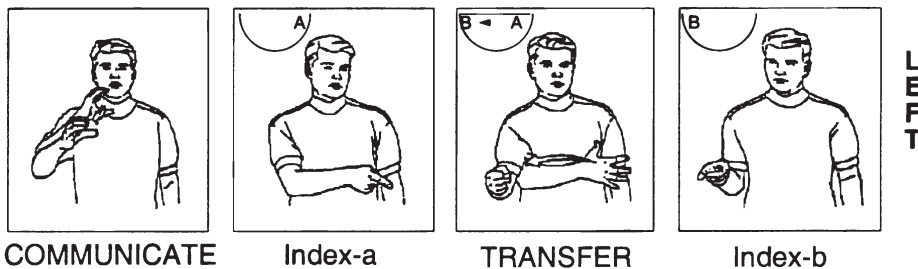


Fig. 6. Left spatial neglect in spatial cognition, but not in language, in RHD signers. Top row shows evidence of left hemispatial neglect in an RHD signer on non-linguistic visuospatial tasks. Bottom row demonstrates the same patient's use of left hemispace in his sign production.

lesions involving posterior language regions (Corina, 1998; Poizner et al., 1987). In addition, the range of common deficit types that have been reported in hearing aphasia has been observed regularly in sign language aphasia. Examples of these include the presence of word (i.e. sign) finding problems in most cases of aphasia, paraphasic errors, and agrammatism, and the tendency for comprehension deficits to be more closely associated with fluent aphasia than with non-fluent aphasia. Based on available evidence, it is reasonable to hypothesize that the functional organization of signed and spoken language within the left hemisphere is very similar.

The following are two illustrative cases of non-fluent and fluent sign aphasia, respectively, in LHD signers.

A case of non-fluent aphasia. LHD- 103-GD's production was halting and effortful, often reduced to single-sign utterances, and lacked all of the syntactic and morphological markings required in ASL; her comprehension, however, was well-preserved. The following is a sample of LHD-103-GD's signing provided by her description of the 'Cookie Theft' picture. The following exchange was carried out in ASL, but for presentation purposes, the examiner's questions

are given in English, and LHD-103-GD's signing in English gloss.

Experimenter: What's that? [Pointing to the picture]
 LHD-103-GD: THREE [pause]
 Experimenter: Who is that? [Pointing to the woman in the picture]
 LHD- 103-GD: MOTHER [pause]
 Experimenter: Who is that? [Pointing to the boy in the picture]
 LHD-103-GD: BROTHER BROTHER [pause]
 Experimenter: What is the woman doing there? [referring to a woman washing dishes]
 LHD-103-GD: [Fumbles and gestures, then signs]
 PLATE T- . . . E- . . . O W L
 [attempts to fingerspell 'towel']

This clinical profile is consistent with Broca's aphasia, and her lesion, involving most of the left frontal lobe and anterior insula, was typical of those that produce Broca's aphasia (including agrammatism) in spoken language.

A case of fluent aphasia. LHD-101-PD's signing was fluent and displayed the full range of ASL's grammatical markers. His use of these grammatical mark-

ers, however, was disordered. His signing was replete with selectional errors and additions within ASL morphology, and exhibited many errors in spatialized syntactic markings of ASL. The following is a sample of LHD-101-PD's signing (asterisks indicate errors):

AND HAVE ONE * WAY-DOWN-THERE [unintelligible]. MAN WALK, MAN SEE THAT
 * DISCONNECT E-X-T-E-N-T-I-O-N O-F *
 EARTH ROOM. HAVE FOR MAN CAN
 * LIVE ROOF, LIGHT, SHADE [Serialized Plural]
 *PULL-DOWNI[+Dual] + Habitual] AND HAVE
 GLASS WALL...

["And there's one (way down at the end) [unintelligible]. The man walked over to see the (disconnected), an extension of the (earth) room. It's there for the man (can live) a roof and light with shades to (keep pulling down)."]

His production is much like that of a Wernicke's aphasic, although his comprehension is relatively preserved which is uncharacteristic of that syndrome. His lesion is subcortical in the left hemisphere involving caudate, lenticular nucleus, and external capsule with extension into the frontal periventricular white matter and white matter undercutting the superior sector of both the frontal and parietal opercula.

The role of Broca's area

Broca's area has figured prominently in attempts to determine the anatomy of speech production (see Dronkers and Larsen, 2001, this volume). While recent studies have shown convincingly that lesions restricted to Broca's area do not lead to a lasting, severe speech production deficit (Mohr, Pessin, Finkelstein et al., 1978), evidence from the acute postictal syndrome (Alexander, Naeser and Palumbo, 1990) as well as evidence from cortical stimulation (Ojemann, 1983; Penfield and Roberts, 1959) and functional neuroimaging (Petersen, Fox, Posner et al., 1988; Zatorre, Meyer, Gjedde et al., 1996) suggests at least some role for Broca's area in speech production. Determining whether Broca's area plays a role in the production of sign language (which uses articulators that are controlled by superior-lateral motor

cortex) will contribute to answering the question, to what extent is the cerebral organization of language areas driven by the cerebral topography of the sensory-motor systems?

We had the opportunity to investigate the role of Broca's area in sign language production through an in-depth case study of LHD-130-RS, a congenitally deaf, native user of ASL, who suffered an ischemic infarct involving the frontal operculum and inferior portion of the primary motor cortex (Hickok, Kritchevsky, Bellugi and Klima, 1996b). Acutely, she presented with mutism, consistent with what one might expect in a hearing/speaking individual. Chronically, LHD-130-RS had good comprehension, fluent production with occasional sign-finding problems, semantic paraphasias, and what appeared to be a deficit involving the ability to coordinate bimanual movements during sign production (Fig. 7). The latter deficit showed up: (1) in LHD-130-RS's tendency on one-handed signs, to 'shadow', with her non-dominant; hand, sign-articulatory gestures carried out by her dominant hand (Fig. 7A); (2) in her tendency on two-handed signs, to assimilate the handshape and/or movement of the non-dominant hand with that of the dominant hand (Fig. 7B); and (3) in her occasional failure to complete the movement of a two-handed sign when the endpoint of the movement involved contact between the two hands (Fig. 7Q). We were not able to find any evidence of a bimanual coordination deficit in non-linguistic tasks. Blumstein has suggested that speech production errors in anterior aphasia reflects a breakdown at the phonetic (not phonemic) level caused by a loss of the ability to coordinate independent speech articulators (e.g. larynx, tongue, lips) (Blumstein, 1995). For a signer, the two hands are independent articulators which are often required to perform independent (i.e. non-symmetric) movements. The deficit observed in LHD-130-RS may represent the sign analogue of phonetic-level breakdown in language production. This case suggests that Broca's area plays an important role in sign-language production.

A case of sign blindness

'Pure Word Blindness' or 'Alexia without Agraphia' has been well-documented in the literature (Friedman and Albert, 1985). Hearing/speaking patients with this

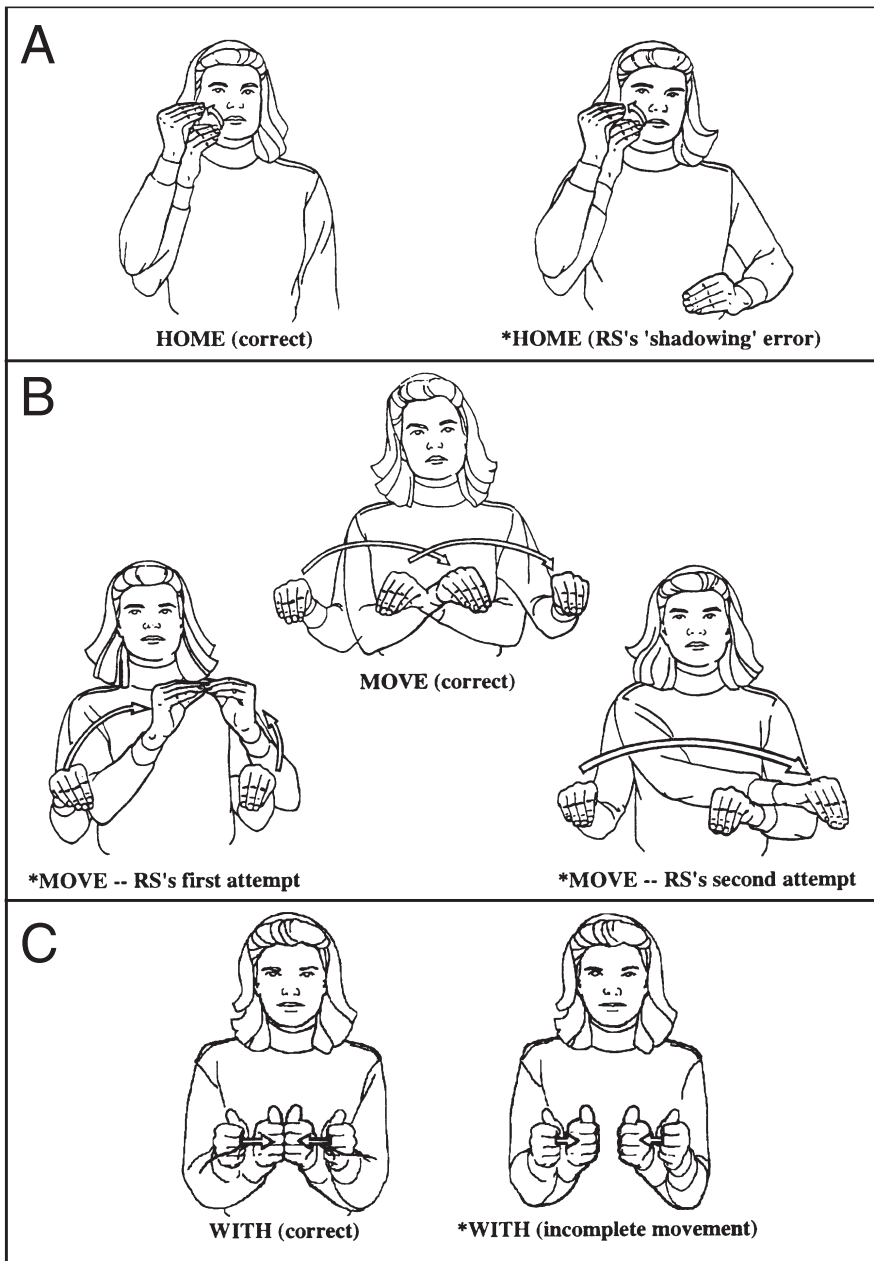


Fig. 7. Examples of bimanual coordination errors in the sign production of a deaf native signer with a lesion in Broca's area. (A) Example of 'shadowing' on unimanual signs. (B) Example of difficulty in articulating signs with asymmetric movements (i.e. movements which involve non-homologous muscle groups in the left and right limbs). (C) Example of failure to complete a bimanual sign in which the endpoint of articulation involved contact of the two hands.

disorder are typically blind in the right visual field (right homonymous hemianopia), have normal auditory-verbal language capacity, are able to write, but cannot read. The lesion typically involves left visual cortex (explaining the visual field defect) and sple-

nium. of the corpus callosum. Language areas are thus preserved, allowing normal production, auditory comprehension, and writing, but these areas are isolated from visual input (because of cortical blindness in the right visual field and deafferentation of infor-

mation coming from the left visual field through the splenium). A deaf signer, LHD- I I I -BC, had a lesion involving all of the left primary visual cortex, most of area 18, with some extension into medial aspects of the temporal lobe (area 37); this lesion also clearly involved white matter fibers lateral to the splenium (Hickok et al., 1995b). Consistent with the neurological effects of such a lesion in hearing subjects, the deaf subject, LHD- I I I -BC, was alexic (i.e. she could not read written English). While her signing was fluent and grammatical, her comprehension was profoundly impaired; she could not follow even simple one-step (ASL) commands, such as “point to the floor”. Her single-sign comprehension was also significantly impaired, although to a lesser extent than her sentence comprehension. Her visual object recognition, however, was unimpaired: she had no problem naming line-drawings of objects presented to her visually. It would appear that LHD- I I I -BC was essentially blind for sign language as a result of her left occipito-temporal lesion that isolated the left hemisphere language systems from visual information, analogous to the neurological model of pure word blindness. This case provides strong evidence favoring the view that the left hemisphere is dominant for ASL in deaf individuals because it demonstrates that the right hemisphere by itself is severely constrained in its ability to process signed language.

Neurology of sign comprehension

Auditory comprehension deficits in aphasia in hearing/speaking individuals are most closely associated with left temporal lobe damage (Naeser, Helm-Estabrooks, Haas et al., 1987). This makes intuitive sense given that the temporal lobe contains primary and secondary auditory fields. Because the sensory input of a deaf signer is via the visual system, one might expect that the temporal lobe plays a less important role in sign language comprehension, with more posterior visual-related cortical fields playing a larger role. We investigated the relative role of the left versus right temporal lobe in the comprehension of ASL (Love, Bellugi, Klima and Hickok, 1999). Nineteen life-long signers with unilateral brain lesions (11 LHD, 8 RHD) performed three tasks, an isolated single-sign comprehension task, a sentence-level comprehension task involving simple one-step commands, and a sentence-

level comprehension task involving more complex multi-clause/multi-step commands. Performance was examined in relation to two factors: whether the lesion was in the right or left hemisphere and whether the temporal lobe was involved or not. The LHD group performed significantly worse than the RHD group on all three tasks confirming left hemisphere dominance for sign language comprehension. The group with left temporal lobe involvement was significantly impaired on all tasks, whereas each of the other three groups performed at better than 95% correct on the single sign and simple sentence comprehension tasks, with performance falling off only on the complex sentence comprehension items (see Fig. 8). A comparison with previously published data (Swisher and Sarno, 1969) suggests that the degree of difficulty exhibited by the deaf RHD group on the complex sentences is comparable to that observed in hearing RHD subjects. This result suggests that language comprehension depends primarily on the integrity of the left temporal lobe, independent of modality.

Dissociations

The functional divisions within the neural systems supporting language and other cognitive abilities have been highlighted by several dissociations observed in deaf signers.

Dissociations between linguistic and non-linguistic spatial abilities

It was noted above that LHD, but not RHD, frequently produces aphasia in deaf signers, whereas RHD, but not LHD, frequently produces gross visuospatial deficits (Fig. 5). This pattern of deficits constitutes a double dissociation between sublexical-, lexical-, and sentence-level aspects of spatialized linguistic ability on the one hand, and gross non-linguistic spatial cognitive ability on the other (Hickok et al., 1996a). Additional dissociations between sign language abilities and non-linguistic spatial abilities have been demonstrated both within the left hemisphere and within the right hemisphere. Within the left hemisphere, we examined the relation between local-level visuospatial deficits evident on a drawing copy task, and several measures of sign language ability, including rate of paraphasias in running sign,

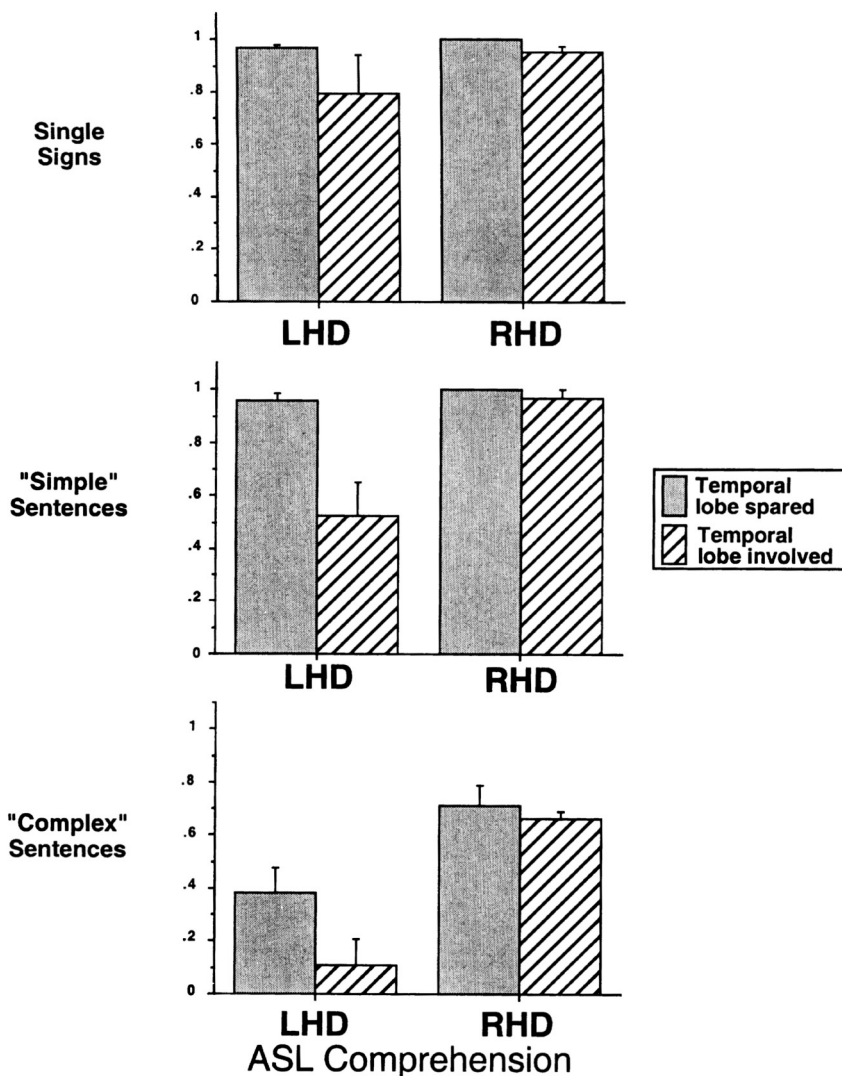


Fig. 8. Comprehension in LHD and RHD deaf signers as a function of hemisphere and temporal lobe involvement.

single-sign comprehension, and sentence-level comprehension (Hickok et al., 1998c). No significant correlations were found between the hit rate for local features in the drawing copy task and any of the sign language performance measures. In fact, cases were identified in which local-level scores were near perfect, yet scores on tests of sign language ability were among the worst in the sample. This suggests that aphasic deficits cannot be reduced to a more general deficit in local-level visuospatial processing. Within performance on standard visuospatial tasks was quite good, yet she had difficulty with spatialized aspects of ASL discourse. This finding hints at the possibility that there are non-identical neural systems within

the right hemisphere supporting spatialized discourse functions versus non-linguistic spatial abilities.

Dissociations within spatialized language systems in ASL

In addition to using space to encode grammatical and discourse information, ASL uses space in an iconic fashion to represent spatial information directly, as, for example, in describing the layout of objects in room. It is worth making the distinction clear between the grammatical use of space in ASL, as in the encoding of phonological, morphological, and syntactic information described previously, and the spatial use of space in ASL (e.g. to directly convey spatial rela-

tions; e.g. Emmorey, Hickok and Klima, 1997). English communicates spatial information through the use of prepositions and spatial description words as in the utterance, “The cup is near the left, front corner of table behind the fork.” Note that the grammatical structure of such a sentence is independent of how accurate the spatial information is. So while it may or may not be the case that the cup is behind the fork, it certainly is the case that the sentence itself follows the rules of the grammatical structure of English (as opposed to “cup near corner left front table”). In ASL, instead of using lexical means (prepositions) to communicate spatial information, the locations of objects relative to one another are physically and more or less iso-morphically (i.e. iconically) mapped out in (signing) space (Fig. 9). And, like in the spoken language example, the grammatical structure of a signed sentence is independent of the truth value of the content.

We wondered whether the grammatical use of space could be dissociated from the spatial use of space even when these types of information are expressed in the same channel. To investigate this question, we tested the performance of two deaf, native signers - one with left hemisphere damage and one with right hemisphere damage - on comprehension tasks involving the use of space, within ASL, to represent grammatical versus spatial information (Hickok, Say, Bellugi and Klima, 1996c). In the grammatical task, we presented signed sentences similar to “the cat chased the dog” in which the grammatical subject and object of the verb was indicated spatially; the task was to select a picture that matched the meaning of the sentence. In the spatial task, we presented a signed description (using classifier constructions) of the layout of furniture in a room followed by a picture that either matched that description or did not; the task was to indicate whether the picture matched the description (Emmorey et al., 1997). We found a double dissociation: the LHD deaf signer (130-RS) was impaired on tasks involving the use of space for encoding grammatical information (64% correct), but performed well on tasks involving the use of space to encode spatial information iconically (100% correct). The RHD deaf signer (216-SJ) showed the reverse pattern (89% and 50%, respectively). These data suggest that the neural organization for language and spatial cognition are driven by the type of represen-

tation that is ultimately constructed from the signal (grammatical vs. spatial), rather than by the physical properties of the signal itself.

Dissociation between aphasia and apraxia

The data discussed thus far suggest that sign language deficits cannot be reduced fully to domain general spatial cognitive deficits. To what extent can sign language deficits be reduced to domain-general motor skills? In order to address this question, we administered an abbreviated version of Kimura’s Movement Copy Test (Kimura, 1993) to 11 LHD subjects. This task involved copying non-representational manual movements using the arm ipsilateral to the lesion. We did find varying degrees of disruption in the ability to perform this task, consistent with the tendency for hearing LHD patients; however, scores did not correlate significantly with measures of sign production during connected sign, including number of paraphasias per minute, number of paraphasias when corrected for number of signs produced, or fluency as defined in the Boston Diagnostic Aphasia Examination phrase length scale (Hickok et al., 1996a). Furthermore, on each of the language measures, subjects could be identified who produced similar scores in terms of their sign production yet differed substantially in their apraxia score, indicating the dissociability between the two domains. While it is difficult to rule out fully the existence of a significant correlation between these variables because of the relatively small sample size, these data suggest that there is a significant amount of variability in at least some aspects of sign language disruption that cannot be accounted for solely by a disruption of voluntary motor control.

Dissociations between sign and gesture

Evidence supporting the view that deficits in sign language are qualitatively different from deficits in the ability to produce and understand pantomimic gesture comes from a case study of a LHD signer (Corina, Poizner, Bellugi et al., 1992). Following an ischemic infarct involving both anterior and posterior perisylvian regions, LHD-108-WL became aphasic for sign language. His comprehension was poor and his sign production was characterized by frequent paraphasias, reduced grammatical structure, and a tendency to

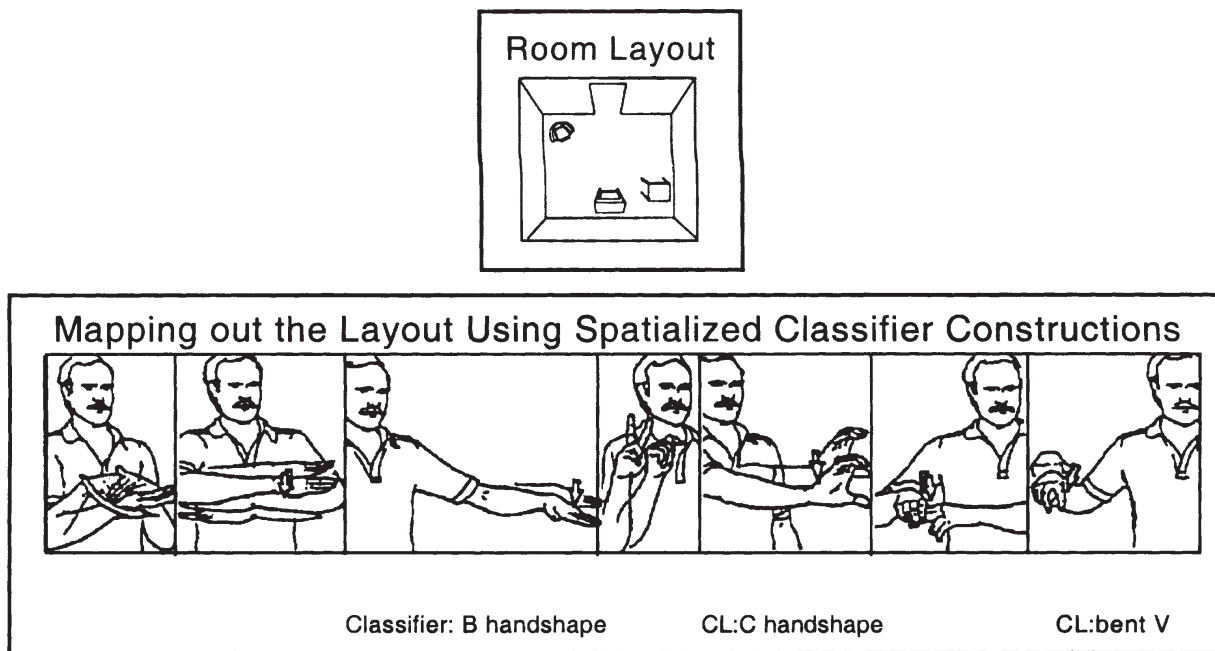


Fig. 9. Illustration of 'spatial mapping' in ASL using classifier constructions. In such mapping from real world space to signing space the identity of each object is specified by lexical sign (e.g. TABLE, TV, CHAIR). The locations of the objects including their orientation and their spatial relations with respect to one another are indicated by a 'classifier' sign, determined by the size and shape of the particular object. The figure shows a description of a room in ASL using classifier constructions (for table, TV and chair) as seen from the door. Where English uses separate words (prepositions, adverbs) to express such spatial relations, ASL uses the actual visual layout displayed by the array of classifier signs to indicate the spatial relations of the objects.

substitute pantomime for ASL signs - a tendency not present prior to his stroke. These pantomimic gestures were used even in cases in which the gesture involved similar or more elaborate sequences of movements arguing against a complexity-based explanation of his performance. LHD- 108-WL showed a similar dissociation in his comprehension of signs versus pantomime where he had more trouble matching a sign to a picture than matching a pantomimed gesture to picture. This case makes the point that disruptions in sign language ability are not merely the result of more general disruptions in the ability to communicate through symbolic gesture.

Converging evidence and additional issues

Evidence from functional neuroimaging

Lesion evidence has indicated clearly that hemispheric asymmetries for signed and spoken language

are similar, and has provided some indication that the within-hemisphere organization of signed language is also similar to that of spoken language. But the spatial resolution of the lesion method is poor, particularly in a rare population, limiting the amount of information one can derive from lesion studies alone. The development of new functional imaging methods has allowed investigators to take a closer look at the within-hemisphere organization of sign language. The first studies examined the role of Broca's area in sign production (Hickok, Clark, Erhard et al., 1995a; McGuire, Robertson, Thacker et al., 1997). Those studies have documented that Broca's area is, in fact, activated during sign production, consistent with lesion evidence (see Fig. 10).

More recent work has examined regions involved in sign language comprehension. Neville et al. (Neville, Bavelier, Corina et al., 1998) asked deaf native signers to watch videotapes of sign language sentences during fMRI acquisition. After subtraction of

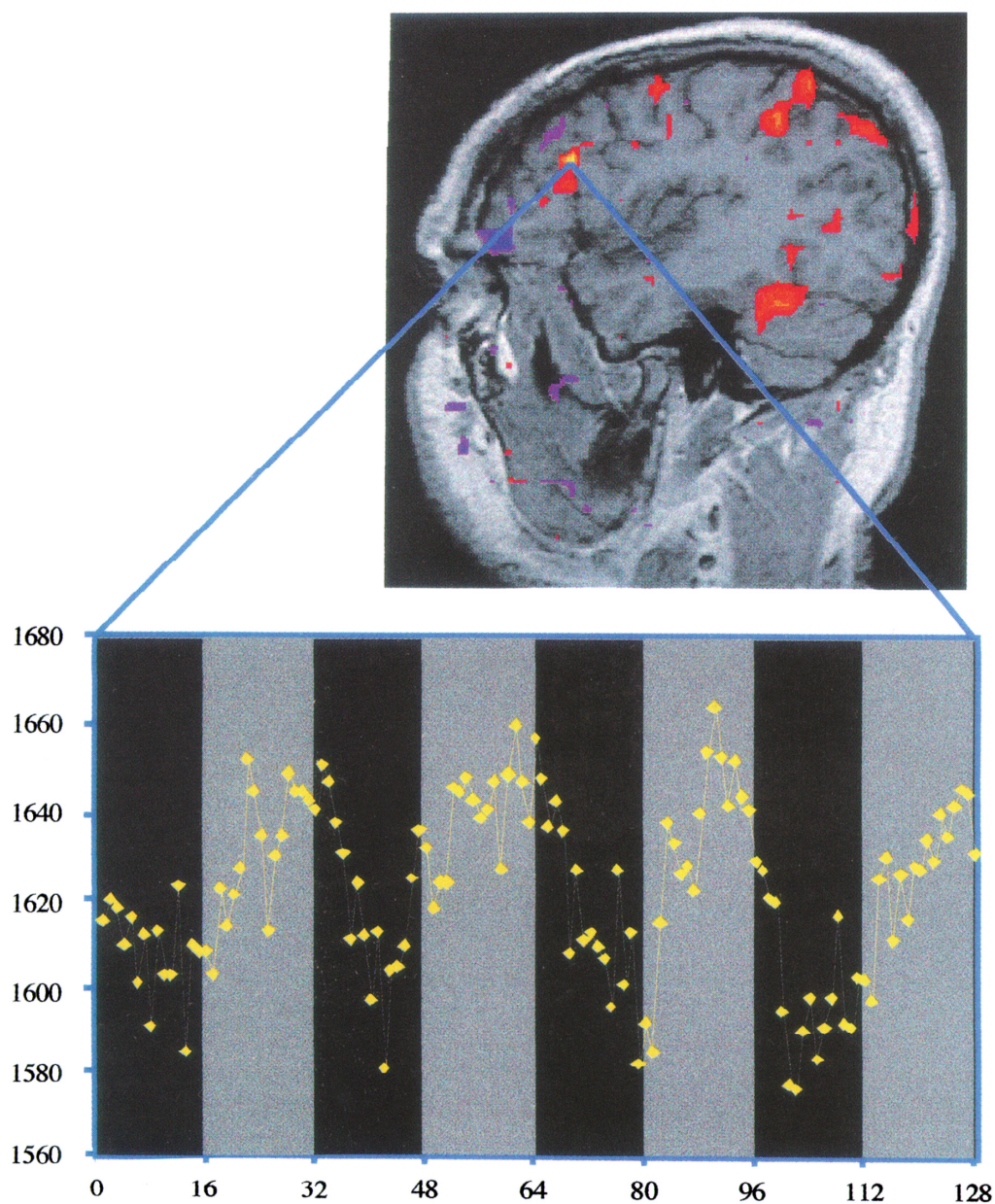


Fig. 10. Activation of Broca's area in a sign language production task. Subjects were shown a grayscale image of a different ASL handshape every 5 s during image acquisition, and asked to generate (covertly) as many ASL signs as possible that incorporate that handshape. Data from Hickok et al. (1995a).

a condition in which participants observed nonsense sign sentences, several regions of activation were found including lateral superior temporal lobe structures and several frontal structures including Broca's area. Parietal lobe regions were not activated, nor were auditory cortices in the supratemporal plane (the dorsal surface of the temporal lobe which contains

primary and secondary auditory cortices). This result shows that many traditional language processing areas within the left hemisphere are activated during sign comprehension, including portions of Wernicke's area as well as Broca's area. Several regions one might expect a priori to be involved in sign language processing were not activated, including parietal lobe

structures and secondary visual cortices. Some authors have emphasized the bilateral activation pattern in the Neville et al. study, and used this observation to argue that ASL may be more bilaterally organized than spoken language (Neville et al., 1998; Paulesu and Mehler, 1998). The lesion evidence, however, clearly indicates a similar pattern of hemispheric asymmetries for signed and spoken language, including comprehension ability (Hickok, Bellugi and Klima, 1998b). To the extent that differences in the degree of hemispheric asymmetries exist between signed and spoken language, they will likely be very subtle.

Plasticity and the 'deaf brain'

There does appear to be one major difference in the neural organization of signed and spoken language, which is highlighted by functional imaging data. A range of studies of auditory language perception have indicated that the dorsal superior temporal gyrus is a site important for speech perception (Boatman, Lesser and Gordon, 1995; Hickok, 2000; Zatorre et al., 1996). This is not surprising given that unimodal auditory cortical fields are located predominantly in the supratemporal plane (Galaburda and Sanides, 1980). Functional imaging studies of sign language perception have noted activations in the lateral temporal lobe (e.g. superior temporal sulcus), but have not reported activation in unimodal auditory cortical regions (Hickok, Poeppel, Clark et al., 1997; Neville et al., 1998; Nishimura, Hashikawa, Doi et al., 1999). This observation is consistent with the hypothesis that unimodal auditory cortical fields are important for speech perception in hearing/speaking individuals, that such systems participate only in auditory language perception, and that canonical unimodal auditory fields in congenitally deaf individuals retain their original functional specification (Hickok et al., 1997). If systems important for speech perception can be found in unimodal auditory cortex, and these systems are not recruited for the perception of sign language, we should expect to find the sign analogue of speech perception to be located somewhere in unimodal *visual* cortex.

Summary

The data reviewed here support the conclusion that the neural organization of signed language is remarkably similar to that of spoken language. Left perisylvian damage in deaf signers produces sign language deficits much like those found in hearing individuals with left perisylvian damage. Furthermore, functional imaging and lesion evidence suggests that Broca's area participates in sign language production and that the lateral temporal lobe is a site critical for sign language comprehension. Right hemisphere damage in deaf signers does not produce marked aphasic deficits, but has been associated with discourse-level sign language deficits. Language abilities in deaf signers appear to be dissociable from a variety of non-linguistic visuospatial abilities, from non-linguistic symbolic-gestural abilities, and from non-symbolic praxic abilities. The sensory interface system seems to constitute the major difference between the neural organization of signed versus spoken language: speech perception appears to rely on systems in the dorsal superior temporal gyrus, sign perception does not appear to activate this region. We hypothesize that the sign analogue of speech perception is carried out in unimodal visual cortex, whereas higher-level (i.e. supramodal) language processes (lexical, morphological, syntactic) are carried out in canonical left perisylvian language regions. Thus, despite a priori expectations, radical differences in the peripheral sensory and motor interface systems between signed and spoken language appear to have little effect on the neural organization of core aspects of the linguistic system. Perhaps there are some intrinsic features of language-related cortical fields that make these areas particularly well-suited for linguistic computation, independent of modality.

Acknowledgements

This research was supported in part by grants from National Institute of Deafness and Communication Disorders (DC00201) and the National Institute of Child Health and Human Development (HD13249) to UB. Illustrations copyright, The Salk Institute for Biological Studies.

References

- Alexander MP, Naeser MA, Palumbo C: Broca's area aphasia: aphasia after lesions including the frontal operculum. *Neurology*:40;353-362,1990.
- Arimatsu Y, Miyamoto M, Nihonmatsu I, Hirata K, Uratani Y, Hatanaka Y et al.: Early regional specification for a molecular neuronal phenotype in the rat neocortex. *Proceedings of the National Academy of Sciences*: 89; 8879-8883, 1992.
- Bellugi U, Poizner H, Klima E: Language, modality, and the brain. *Trends in Neurosciences*: 10; 380-388, 1989.
- Blumstein S: The neurobiology of the sound structure of language. In Gazzaniga MS (Ed), *The Cognitive Neurosciences*. Cambridge, MA: MIT Press, pp. 913-929, 1995.
- Boatman D, Lesser RP, Gordon B: Auditory speech processing in the left temporal lobe: an electrical interference study. *Brain and Language*: 51; 269-290, 1995.
- Brownell HH, Potter HH, Bihle AM, Gardner H: Inference deficits in right brain-damaged patients. *Brain and Language*: 27;310-321,1986.
- Clark K, Hickok G, Batch L, Bellugi U, Klima ES, Kritchevsky M: Dissociations between spatially organized discourse and non-language spatial cognition in American sign language following right hemisphere damage. *Brain and Language*: 51; 198-200,1995.
- Corina D: The processing of sign language: evidence from aphasia. In *Handbook of Neurolinguistics*. San Diego, CA: Academic Press, pp. 313-329, 1998.
- Corina D, Kritchevsky M, Bellugi U: Visual language processing and unilateral neglect: evidence from American Sign Language. *Cognitive Neuropsychology*: 13; 321-356, 1996.
- Corina D, Poizner H, Bellugi U, Feinberg T, Dowd D, O'Grady-Batch L: Dissociation between linguistic and non-linguistic gestural systems: a case for compositionality. *Brain and Language*: 43; 414-447, 1992.
- Corina D, Sandler W: On the nature of phonological structure in sign language. *Phonology*: 10; 165-207, 1993.
- Damasio AR: Aphasia. *New England Journal of Medicine*: 326; 531-539,1992.
- Delis D, Kiefner MG, Fridlund AJ: Visuospatial dysfunction following unilateral brain damage: dissociations in hierarchical and hemispatial analysis. *Journal of Clinical and Experimental Neuropsychology*: 10; 421-431, 1988.
- DeRenzi E, Vignolo LA: The token test: a sensitive test to detect receptive disturbances in aphasics. *Brain*: 85; 665-678, 1962.
- Dronkers NF, Larsen J: Neuroanatomy of the classical syndromes of aphasia. In Berndt RS (Ed), *Language and Aphasia, Hand book of Neurophysiology*, 2nd ed., Vol. 3. Amsterdam: Elsevier, pp. 19-30, 2001.
- Emmory K, Hickok G, Klima E: The neural organization for sign language: insights from right hemisphere damaged signers. *Brain and Cognition*: 32(2); 212-215, 1997.
- Friedman RB, Albert ML: Alexia. In Heilman KM, Valenstein E (Eds), *Clinical Neuropsychology*. New York: Oxford University Press, pp. 49-73, 1985.
- Galaburda A, Sanides F: Cytoarchitectonic organization of the human auditory cortex. *Journal of Comparative Neurology*: 190;597-610,1980.
- Goodglass H: *Understanding Aphasia*. San Diego, CA: Academic Press, 1993.
- Goodglass H, Kaplan E: *The Assessment of Aphasia and Related Disorders*. Philadelphia, PA: Lea and Febiger, 1983.
- Heilman KM, Watson RT, Valenstein E: Neglect: clinical and anatomic aspects. In Feinberg TE, Farah MJ (Eds), *Behavioral Neurology and Neuropsychology*. New York: McGraw-Hill, pp.309-317,1997.
- Hickok G: Speech perception, conduction aphasia, and the functional neuroanatomy of language. In Grodzinsky Y, Shapiro L, Swinney D (Eds), *Language and the Brain*. San Diego, CA: Academic Press, pp. 87-104, 2000.
- Hickok G, Bellugi U, Klima ES: The neural organization of language: evidence from sign language aphasia. *Trends in Cognitive Sciences*: 2; 129-136, 1998a.
- Hickok G, Bellugi U, Klima ES: What's right about the neural organization of sign language? A perspective on recent neuroimaging results. *Trends in Cognitive Science*: 2; 465-468, 1998b.
- Hickok G, Clark K, Erhard P, Helms-Tillery K, Naeve-Velguth S, Adriany G et al.: Effect of modality on the neural organization for language: an fMRI study of sign language production. *Society for Neuroscience Abstracts*: 21; 694,1995a.
- Hickok G, Kirk K, Bellugi U: Hemispheric organization of local-and global-level visuospatial processes in deaf signers and its relation to sign language aphasia. *Brain and Language*: 65; 276-286,1998c.
- Hickok G, Klima ES, Bellugi U: The neurobiology of signed language and its implications for the neural basis of language. *Nature*: 381; 699-702, 1996a.
- Hickok G, Klima E, Kritchevsky M, Bellugi U: A case of 'sign blindness' following left occipital damage in a deaf signer. *Neuropsychologia*: 33; 1597-1606, 1995b.
- Hickok G, Kritchevsky M, Bellugi U, Klima ES: The role of the left frontal operculum in sign language aphasia. *Neurocase*: 2; 373-380,1996b.
- Hickok G, Poeppel D, Clark K, Buxton R, Rowley HA, Roberts TPL: Sensory mapping in a congenitally deaf subject: MEG and fMRI studies of cross-modal non-plasticity. *Human Brain Mapping*: 5; 437-444, 1997.
- Hickok G, Say K, Bellugi U, Klima ES: The basis of hemispheric asymmetry for language and spatial cognition: clues from focal brain damage in two deaf native signers. *Aphasiology*: 10; 577-591, 1996c.
- Hickok G, Wilson M, Clark K, Klima ES, Kritchevsky M, Bellugi U: Discourse deficits following right hemisphere damage in deaf signers. *Brain and Language*: 66; 233-248, 1999.

- Kimura D: Neural mechanisms in manual signing. *Sign Language Studies*: 33; 291-312, 1981.
- Kimura D: *Neuromotor Mechanisms in Human Communication*. Oxford: Oxford University Press, 1993.
- Kirk A, Kertesz A: Localization of lesions in constructional impairment. In Kertesz A (Ed), *Localization and Neuroimaging in Neuropsychology*. San Diego, CA: Academic Press, pp. 525-544, 1994.
- Klima E, Bellugi U: *The Signs of Language*. Cambridge, MA: Harvard University Press, 1979.
- Liddell S: *American Sign Language Syntax*. New York: Mouton, 1980.
- Lillo-Martin D: *Universal Grammar and American Sign Language: Setting the Null Argument Parameters*. Boston, MA: Kluwer Academic Publishers, 1991.
- Love T, Bellugi U, Klima ES, Hickok G: Left temporal lobe supports sign language comprehension. In *Cognitive Neuroscience Society Annual Meeting Program 1999*, p. 96, 1999.
- McGuire PK, Robertson D, Thacker A, David AS, Kitson N, Frackowiak RS et al.: Neural correlates of thinking in sign language. *NeuroReport*: 8; 695-698, 1997.
- Miyashita-Lin EM, Hevner R, Wassarman KM, Martinez S, Rubenstein JLR: Early neocortical regionalization in the absence of thalamic enervation. *Science*: 285; 906-909, 1999.
- Mohr JP, Pessin MS, Finkelstein S, Funkenstein HH, Duncan GW, Davis KR: Broca's aphasia: pathological and clinical. *Neurology*: 28; 311-324, 1978.
- Naeser MA, Helm-Estabrooks N, Haas G, Auerbach S, Srinivasan M: Relationship between lesion extent in 'Wernicke's area' on computed tomographic scan and predicting recovery of comprehension in Wernicke's aphasia. *Archives of Neurology*: 44; 73-82, 1987.
- Neville H, Bavelier D, Corina D, Rauschecker J, Kami A, Lalwani A et al.: Cerebral organization for language in deaf and hearing subjects: biological constraints and effects of experience. *Proceedings of the National Academy of Sciences*: 95; 922-929, 1998.
- Newport EL: Contrasting conceptions of the critical period for language. In Carey S, Gelman R (Eds), *The Epigenesis of Mind: Essays in Biology and Cognition*. Hillsdale, NJ: Lea, pp. 111-130, 1991.
- Newport E, Meier R: The acquisition of American Sign Language. In Slobin DI (Ed), *The Crosslinguistic Study of Language Acquisition: Volume 1: The Data*. Hillsdale, NJ: Lea, pp. 881-938, 1985.
- Nishimura H, Hashikawa K, Doi K, Iwaki T, Watanabe Y, Kusuoka H et al.: Sign language 'heard' in the auditory cortex. *Nature*: 397; 116, 1999.
- Nothias F, Fishell G, Ruiz i Altaba A: Cooperation of intrinsic and extrinsic signal in the elaboration of regional identity in the posterior cerebral cortex. *Current Biology*: 8; 459-462, 1998.
- O'Leary DDM: Do cortical areas emerge from a protocortex. *Trends in Neurosciences*: 12; 400-406, 1989.
- Ojernann GA: Brain organization for language from the perspective of electrical stimulation mapping. *Behavioral and Brain Sciences*: 6; 189-230, 1983.
- Paulesu E, Mehler J: Right on in sign language. *Nature*: 392; 233-234, 1998.
- Penfield W, Roberts L: *Speech and Brain-Mechanisms*. Princeton, NJ: Princeton University Press, 1959.
- Perlmutter DM: Sonority and syllable structure in American Sign Language. *Linguistic Inquiry*: 23; 407-442, 1992.
- Petersen SE, Fox PT, Posner MI, Mintun M, Raichle ME: Positron emission tomographic studies of the cortical anatomy of single-word processing. *Nature*: 331; 585-589, 1988.
- Poizner H, Kegl J: Neural disorders of the linguistic use of space and movement. *Annals of the New York Academy of Sciences*: 682; 192-213, 1993.
- Poizner H, Klima ES, Bellugi U: *What the Hands Reveal About the Brain*. Cambridge, MA: MIT Press, 1987.
- Pons TP, Garraghty PE, Ommaya AK, Kaas JH, Taub E, Mishkin M: Massive cortical reorganization after sensory deafferentation in adult macaques. *Science*: 252; 1857-1860, 1991.
- Rakic P: Specification of cerebral cortical areas. *Science*: 241; 170-176, 1988.
- Sadato N, Pascual-Leone A, Grafman J, Ibanez V, Deiber MP, Dold G et al.: Activation of the primary visual cortex by Braille reading in blind subjects. *Nature*: 380; 526-528, 1996.
- Schlaggar BL, O'Leary DDM: Potential of visual cortex to develop an array of functional units unique to somatosensory cortex. *Science*: 252; 1556-1560, 1991.
- Sur M, Garraghty PE, Roe AW: Experimentally induced visual projections into auditory thalamus and cortex. *Science*: 242; 1437-1441, 1988.
- Swisher LP, Sarno MT: Token Test scores of three matched patient groups: Left brain-damaged with aphasia, right brain-damaged without aphasia, non-brain damaged. *Cortex*: 5; 264-273, 1969.
- Tallal P, Miller S, Fitch RH: Neurobiological basis of speech: a case for the preeminence of temporal processing. *Annals of the New York Academy of Sciences*: 682; 27-47, 1993.
- Wapner W, Hamby S, Gardner H: The role of the right hemisphere in the apprehension of complex linguistic materials. *Brain and Language*: 14; 15-33, 1981.
- Zatorre RJ, Meyer E, Gjedde A, Evans AC: PET studies of phonetic processing of speech: review, replication, and reanalysis. *Cerebral Cortex*: 6; 21-30, 1996.