

## Cerebral Morphologic Distinctions Between Williams and Down Syndromes

Terry L. Jernigan, PhD; Ursula Bellugi, EdD; Elizabeth Sowell; Sally Doherty, PhD; John R. Hesselink, MD

• Neurobehavioral studies of Williams syndrome (WS) and Down syndrome (DS) have revealed distinct profiles of cognitive strengths and weaknesses. In a previous report, we described several gross brain morphologic distinctions on magnetic resonance images between these two disorders. While the observed cerebral hypoplasia was of equal degree in the two groups, cerebellar size was entirely normal in the subjects with WS but dramatically reduced in subjects with DS. In WS, paleocerebellar vermal lobules subtended a smaller area on midsagittal sections, but neocerebellar lobules were actually larger. These results suggested important distinctions between WS and DS in terms of the action and anatomic targets of factors that alter brain development in these syndromes. The present study extends the earlier findings by focusing in detail on the morphologic features of the cerebral hemispheres, particularly cerebral gray matter. The results suggest that some frontal and temporal limbic structures are relatively preserved in WS, while some basal ganglia and diencephalic structures are relatively preserved in DS.

(*Arch Neurol.* 1993;50:186-191)

Williams syndrome (WS) is a rare developmental disorder characterized by mental retardation.<sup>1-4</sup> Several reports have appeared describing the nature of the neuropsychological deficits observed in subjects with WS,<sup>5,7</sup> most noting their particularly poor visuospatial and visuomotor abilities and/or their relatively spared linguistic abilities. These studies have generally contrasted the performances of subjects with WS on standardized tests with those of IQ-matched controls who had mixed, or nonspecific, developmental disorders. In a series of recent neurobehavioral investigations, the unusual profile of higher cognitive functions in subjects with WS has been illuminated. These studies

focused first on carefully selected children with WS who were clearly diagnosed as having WS by genetic or metabolic markers, and who were all in a similar state of development (10 years of age and above). The children with WS were contrasted with children with another well-defined genetically based disorder of mental retardation, Down syndrome (DS); the children with DS were matched to the subjects with WS in age, gender, background, and IQ. Moreover, the same subjects underwent a battery of tests across disciplines, including neurologic examinations, and involving standardized and experimental measures of linguistic, visuospatial, cognitive, and affective function. They also underwent magnetic resonance imaging and neurophysiologic probes. Highly distinct neuropsychological profiles for WS vs DS have emerged from these experimental paradigms.<sup>8-14</sup> Perhaps the most striking differences between the groups occurred on probes of linguistic vs visuospatial abilities.

While measures of language that conflate general cognitive and linguistic abilities, such as the Vocabulary subtest from the Wechsler Intelligence Scale for Children-Revised (which requires well-formed definitions), reveal equally severe deficits in both WS and DS, experimental probes of specifically linguistic processing yield striking differences between the two groups. The subjects with WS show a significant advantage on measures of lexical knowledge, word fluency, and other measures of semantic and syntactic competence. Moreover, the children with WS exhibit rich and unusual semantic organization.<sup>9</sup>

In the visuospatial domain, although such global tests as the Developmental Test of Motor Integration<sup>15</sup> and the Wechsler Intelligence Scale for Children-Revised Block Design subtest suggest similar deficits in DS and WS, it is the subjects with DS who show an advantage on tests involving spatial integration.<sup>10</sup> Experimental studies of visuospatial functions have revealed intriguing qualitative differences between the performances of subjects with WS and DS.<sup>12,13</sup> By means of a paradigm employing hierarchical stimuli with information at both the global and local processing levels,<sup>16-18</sup> subjects with WS were shown to use local form information disproportionately, while subjects with DS showed an advantage for global forms. Again, this pattern emerged in the context of equally impaired overall performance in the two groups. Interestingly, previous neuropsychological studies with this task have suggested

Accepted for publication June 25, 1992.

From the San Diego (Calif) Veterans Affairs Medical Center (Dr Jernigan), Departments of Psychiatry (Dr Jernigan), Radiology (Drs Jernigan and Hesselink), and Neurosciences (Dr Hesselink), University of California, San Diego School of Medicine, Laboratory for Cognitive Neuroscience, The Salk Institute (Drs Bellugi and Doherty), La Jolla; and San Diego State University/University of California, San Diego, Joint Doctoral Program in Clinical Psychology (Ms Sowell).

Reprint requests to Department of Psychiatry, 0631P, University of California at San Diego, 9500 Gilman Dr, La Jolla, CA 92093-0631 (Dr Jernigan).

a larger role for the left hemisphere in the processing of local form information and right-hemisphere superiority for the processing of global forms.

Another interesting contrast occurs on tests of facial discrimination. Subjects with WS demonstrate a selective ability to discriminate unfamiliar faces, while subjects with DS are markedly impaired.<sup>10</sup> Preservation of this function in subjects with WS is surprising in light of the severe impairment they show on other tasks requiring the integration of visuospatial information.

Finally, recently completed studies of the use of affect in language suggest further dramatic differences between the groups.<sup>14</sup> The subjects with WS make abundant use of affective prosody and other affective linguistic devices in their narratives, perhaps even more than do normal subjects, whereas the subjects with DS employ few.

Our brain imaging studies of these subjects have attempted to identify anatomic distinctions between the groups that might shed some light on the neural bases of these complex behavioral differences. In our previous report,<sup>19</sup> we described several gross brain morphologic distinctions on magnetic resonance images between these two disorders. While the cerebral hypoplasia observed was of equal degree in two IQ-matched groups, cerebellar size was entirely normal in the subjects with WS, while cerebellar hypoplasia was at least as severe in DS as was cerebral hypoplasia. In addition, measurements of vermal lobules in subjects with WS and controls suggested that while paleocerebellar lobules tended to subtend a smaller area on midsagittal sections, neocerebellar lobules were actually larger. These results suggested important distinctions between WS and DS in terms of the action and anatomic targets of factors that alter brain development in these syndromes. The present study extends the earlier findings by focusing in detail on the morphologic features of the cerebral hemispheres, particularly cerebral gray matter, in larger groups of subjects with DS and WS and a group of age- and gender-matched controls.

## SUBJECTS AND METHODS

### Subjects

Nine subjects with WS (six female and three male) were studied. They ranged in age from 10 to 20 years (mean  $\pm$  SD, 14.7  $\pm$  3.4 years). The six subjects with DS (four female and two male) were also between 10 and 20 years of age (mean, 15.5  $\pm$  3.4 years). The full-scale IQ on the Wechsler Intelligence Scale for Children-Revised was similar in the subjects with WS (mean, 51.6  $\pm$  8.47) and DS (mean, 52.5  $\pm$  8.26). IQ testing was not performed in one of the nine subjects with WS, who lived in another city and was unable to return for testing; however, her intellectual abilities were considered to be comparable with those of other subjects with WS whom we tested. The diagnosis of WS was made on the basis of clinical criteria described by Jones and Smith<sup>3</sup> and confirmed in most cases by Jones and by neuroendocrine markers.<sup>20,21</sup> The diagnosis of DS was made by a physician on the basis of distinct physical features and mental retardation and confirmed by karyotype analysis whenever possible. Subjects with WS and DS were enrolled in the same classes for the educable mentally retarded and drawn from similar socioeconomic backgrounds. Six of the subjects with WS and three of the subjects with DS were also subjects in our earlier neuroanatomic report.<sup>19</sup>

A group of 21 normal controls (13 female and eight male) was also examined. They ranged in age from 10 to 24 years (mean, 14.5  $\pm$  3.8 years). These subjects were screened for history of serious medical illness or developmental or intellectual disabilities.

Of the 21 controls, 18 were right-handed and three were left-handed. Six of the subjects with WS were right-handed and

two were left-handed. All six of the subjects with DS were right-handed. An analysis comparing the incidence of left-handedness in the three groups yielded a  $\chi^2$  statistic with  $P > .3$ , suggesting that handedness was unlikely to affect group comparisons on the brain structural measures.

### Imaging Protocol

Magnetic resonance imaging was performed with a 1.5-T superconducting magnet (Signa, General Electric Co, Milwaukee, Wis) at the University of California, San Diego/American Medical International Magnetic Resonance Institute. Two spatially registered images were obtained simultaneously for each section, by means of an asymmetric, multiple-echo sequence (repetition time, 2000 milliseconds; echo times, 25 and 70 milliseconds; two excitations) to obtain images of the entire brain in the axial plane. Section thickness was 5 mm, with a 2.5-mm gap between successive sections. A 256  $\times$  256 matrix and 24-cm field of view were used.

### Image Analysis

Three subcortical structures and three cortical regions were examined. The volumes of caudate nuclei, lenticular nuclei, and the thalamic and hypothalamic (diencephalic) structures were computed, as were separate volumes of anterior, posterior, and temporal limbic cortex. Detailed descriptions of the image-analytic approach used in the present study are contained in several articles.<sup>19,22-26</sup> Briefly, each pixel location within a section of the imaged brain was classified on the basis of its signal values in the two original images as most resembling cerebrospinal fluid, gray matter, white matter, or signal hyperintensity (tissue abnormality). Consistently identifiable anatomic landmarks and structural boundaries were then designated by trained image analysts who were unaware of any subject characteristics. The processed image data were then transformed spatially so that all locations within the brain images could be identified relative to a common anatomic coordinate system (ie, stereotactically). Cerebral regions were then defined either entirely manually or, when boundaries could not be visually identified on a reliable basis, with the use of a combination of manual and stereotactic procedures.

To define anatomically consistent cortical regions, a method was adopted for making subdivisions of the cerebrum relative to the centromedial structural midline and two consistently identifiable points: the most anterior midline point in the genu and the most posterior midline point in the splenium of the corpus callosum. By calculation of rotation angles with these landmarks, it was possible to perform a three-dimensional rotation of the images, thus correcting each individual's image data for rotation out of the optimal imaging plane. Cortical regions could then be constructed that resulted in highly consistent placement of regional boundaries relative to gross anatomic landmarks.

The orientation of the midsagittal plane was first determined by computing a regression line through a series of visually selected brain-stem midline points. The division of the cerebrum was then based on two major planes (Fig 1): an *axial plane*, which is perpendicular in orientation to the midsagittal plane and passes through the two corpus callosum points, and a *coronal plane*, which is defined as perpendicular to the first plane and which passes through the midpoint between the two corpus callosum points. New coordinates for each voxel were then computed relative to these planes.

The voxels designated as within the caudate, lenticular, and diencephalic regions are highlighted in black in the representative, digitally processed images shown in Fig 2. It should be noted that although the operators circumscribe the entire putamen and globus pallidus, areas within the lenticular nucleus containing significant iron deposits, particularly in the globus pallidus, do not meet the signal criteria for gray matter and are thus not included in this region.

Volumes of the infratentorial and supratentorial cranial vaults were estimated, as in the previous study, by summing infratentorial or supratentorial voxels (including cerebrospinal fluid, hy-

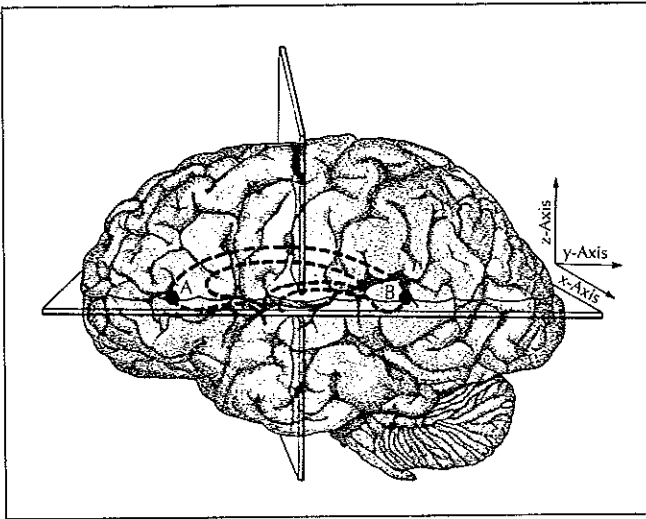


Fig 1.—Cerebral regions are defined as follows. Points A and B in the corpus callosum, shown above, are the most anterior midline point in the genu and the most posterior midline point in the splenium, respectively. An axial plane passing through these two points is defined, as shown, perpendicular to the midsagittal plane. A coronal plane is defined perpendicular to the axial plane and passing through the midpoint between points A and B. This coronal plane divides the cerebrum into an anterior and a posterior zone.

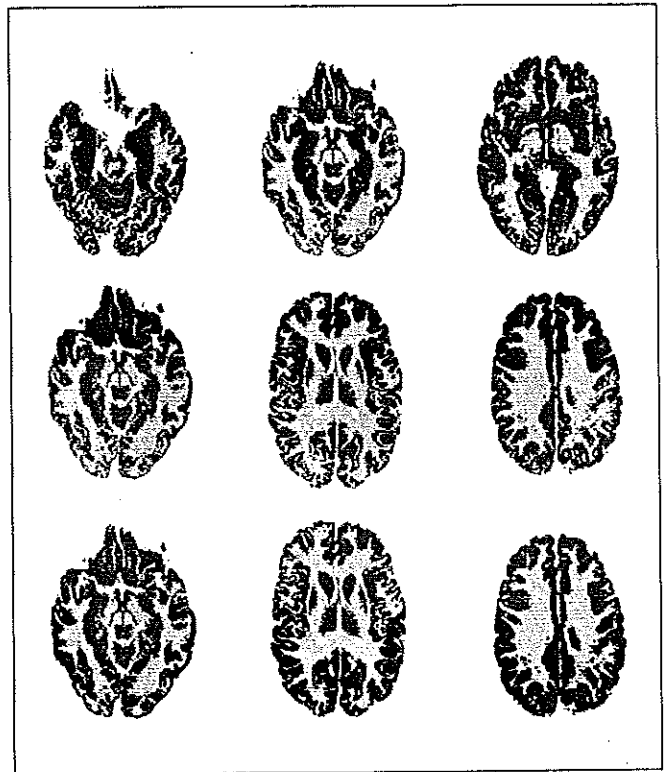


Fig 3.—Representative processed images illustrating definition of cortical regions. Pixels within temporal limbic (top), anterior (center), and posterior cortex (bottom) are highlighted in black.

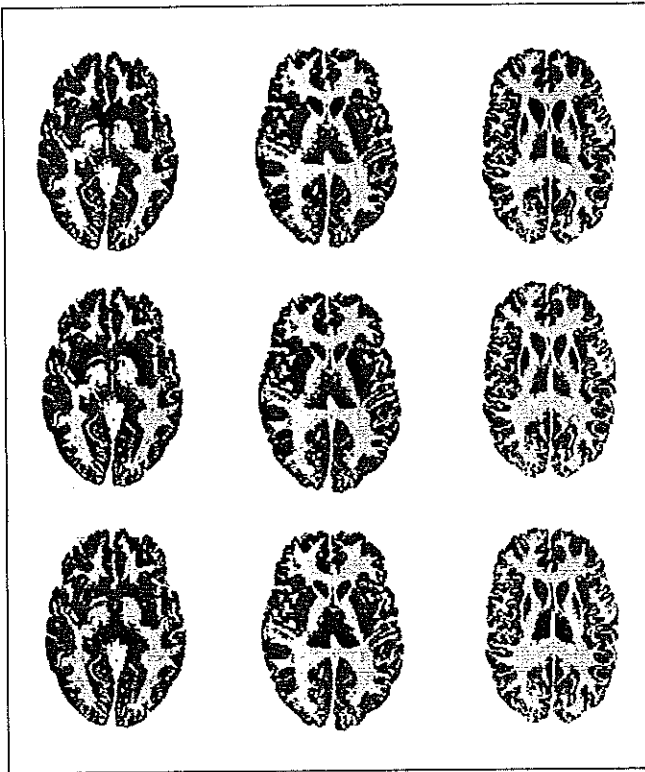


Fig 2.—Representative processed images illustrating definition of sub-cortical gray-matter regions. Pixels within caudate nuclei (top), lenticular nuclei (center), and diencephalic regions (bottom) are highlighted in black.

perintensities, and gray and white matter) over all sections. The cortical gray-matter voxels designated as temporal limbic region are highlighted in black in the images shown in Fig 3, top. All other cortical gray-matter voxels were assigned either to the anterior region (Fig 3, center), ie, anterior to the coronal plane shown

in Fig 1, or to the posterior region (Fig 3, bottom). Additionally, each structure was measured separately for each hemisphere, for the purpose of examining asymmetries. To examine pattern differences between the groups, regional gray-matter volumes were expressed as proportions of the total cerebral gray-matter volume (sum of all regions).

The volume estimates in this study are provided as voxel sums. Each voxel represents 6.59 mm<sup>3</sup> (which includes the 5-mm section and the 2.5-mm gap between sections); therefore, the volumes may be estimated in cubic millimeters by multiplying the voxel sums by 6.59.

#### Statistical Analysis

Group comparisons of the mean volumes and proportions were made by means of Kruskal-Wallis nonparametric analyses of variance and Mann-Whitney *U* tests for two-group comparisons.

#### RESULTS

Global analyses, summarized in Table 1, of the volumes of the supratentorial and infratentorial cranial vaults yielded results virtually identical to those reported previously with the smaller groups. Although the cerebellum was significantly larger in WS than in DS (and was, in fact, normal in size), the supratentorial (cerebral) volume was equally reduced in WS. Total cerebral gray matter, like the total volume of the supratentorial vault, showed a highly significant reduction in both retarded groups, but no difference was obtained between subjects with WS and subjects with DS.

Since the reduction in cerebral gray matter was approximately equal in the two groups, a pattern analysis was conducted in which each regional volume was expressed as a proportion of this total gray-matter volume. This regional analysis of cerebral gray matter is summarized in Table 2. When the anterior and posterior cortical regions

**Table 1.—Global Analyses of Volumes of the Supratentorial and Infratentorial Cranial Vaults\***

Region	Group Means			Statistical Test			
	C (N=21)	WS (N=9)	DS (N=6)	K-W	Mann-Whitney $U \chi^2$		
					C/WS	WS/DS	C/DS
Cerebral	189 292	164 307	156 146	16.1†	9.89‡	0.89	9.92‡
Cerebellar	26 023	25 110	20 033	15.8†	1.78	10.13‡	13.5†
Cerebral gray	100 459	88 034	83 483	11.2‡	7.01‡	1.13	6.59§

\*C indicates control; WS, Williams syndrome; DS, Down syndrome; and K-W, Kruskal-Wallis analysis of variance. Volumes are expressed as voxel sums.

† $P < .001$ .

‡ $P < .01$ .

§ $P < .05$ .

**Table 2.—Regional Analysis of Cerebral Gray Matter Proportions\***

Region	Group Means			Statistical Test			
	C (N=21)	WS (N=9)	DS (N=6)	K-W	Mann-Whitney $U \chi^2$		
					C/WS	WS/DS	C/DS
Anterior cortex	0.389	0.376	0.353	11.0†	2.30	4.50‡	9.55†
Posterior cortex	0.491	0.505	0.524	9.2‡	2.88§	2.72§	7.51†
Temporal limbic cortex	0.056	0.058	0.048	7.2‡	0.32	5.56‡	6.00‡
Caudate nucleus	0.020	0.019	0.021	2.9	0.95	2.35	1.50
Lenticular nucleus	0.022	0.021	0.026	13.4†	0.15	9.39†	12.25
Diencephalon	0.023	0.021	0.027	10.1†	2.44	8.68†	5.72‡

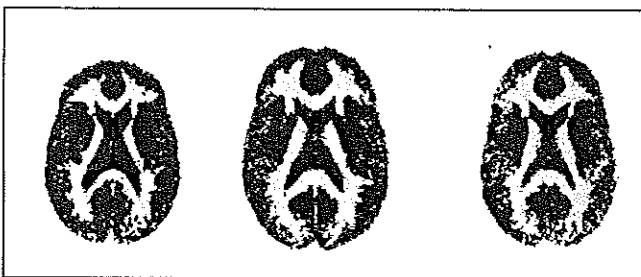
\*C indicates control; WS, Williams syndrome; DS, Down syndrome; and K-W, Kruskal-Wallis analysis of variance.

† $P < .01$ .

‡ $P < .05$ .

§ $P < .10$ .

|| $P < .001$ .



**Fig 4.**—The midcallosal plane through the modal three-dimensional morphologic map for all subjects with Down syndrome (left), all control subjects (center), and all subjects with Williams syndrome (right). The decreased cerebral size in subjects with Down syndrome and Williams syndrome relative to controls is easily seen. The increased ventricular size, decreased frontal lobe volume, and normal thalamic volume in subjects with Down syndrome are also apparent.

were examined separately, a significant difference emerged between the two groups, with the subjects with DS being significantly more hypofrontal than either those with WS or control subjects. Although the subjects with WS were slightly more hypofrontal than controls were, this difference did not reach significance. The pattern observed within the limbic and brain-stem regions revealed a further dissociation between DS and WS. The subjects with DS had significantly greater relative volume reductions in the limbic region, while no difference was observed between subjects with WS and control subjects. In fact, not only was

the limbic proportion normal in WS, but the absolute limbic volume was the only one of the regional volumes that did not show a significant reduction in subjects with WS relative to controls ( $P > .10$ ).

In contrast, the diencephalic and lenticular proportions were both significantly increased in subjects with DS relative to both subjects with WS and controls. This is due to the fact that the subjects with WS showed reductions in these structures comparable with their overall cerebral reductions, while absolute diencephalic and lenticular volumes were completely normal in subjects with DS ( $P > .50$ ). The results for the caudate nuclei revealed reductions of similar magnitude for both retarded groups. No significant group differences were observed for the caudate proportions. The absolute caudate volumes were significantly reduced in subjects with WS relative to controls, and the difference between subjects with DS and controls approached significance.

Left-right ratios of all regions were examined, but only one, for the limbic region, showed a significant difference between the three groups ( $P < .05$ ). This was due to an aberrant right-greater-than-left (0.85) ratio in the subjects with DS relative to the virtually symmetric values for controls and subjects with WS (0.97 and 0.96, respectively).

To provide a visual summary of the results, stereotactically standardized representations of the morphologic features observed in each group were computed from the fully processed images. This involved determining for each subject which tissue category (white matter, gray

matter, cerebrospinal fluid, or signal hyperintensity) was present at each location within the three-dimensional stereotactic space. Then, for each group separately, the modal tissue (among members of the group) was similarly determined for each location. A single standard plane (through the midportions of the genu and splenium of the corpus callosum) through these modal maps is shown in Fig 4 for each of the groups. The differences established by statistical comparisons of the volumes are visually discernible in these group-modal images.

#### COMMENT

To summarize, these comparisons of the sizes of structures within the cerebrum in DS and WS provide further support for important distinctions between the neurodevelopmental processes associated with these disorders. The cerebrum in WS is small; however, the frontal cortex appears to acquire an essentially normal volume relationship to the posterior cortex. In contrast, frontal cortex is disproportionately reduced in volume in DS. Limbic structures of the temporal lobe (including uncus, amygdala, hippocampus, and parahippocampal gyrus) appear to be spared in WS relative to other cerebral structures, while in DS such structures are dramatically reduced in volume. The opposite pattern is observed in several subcortical structures, specifically in regions including thalamus, putamen, and globus pallidus. The volumes of these structures are entirely normal in DS despite dramatic overall brain size reductions.

These cerebral distinctions, together with differences within cerebellar structures reported earlier, suggest that relatively intact linguistic, affective, and face processing functions in WS may rely on relatively normal development of some limbic, frontal cortical, and cerebellar structures. Leiner et al<sup>27</sup> recently proposed that a cerebellofrontocortical system has evolved in humans to support the processing demands of fluent speech, pointing out that large increases in the sizes of these structures occur in humans relative to apes. Thus, the relative sparing of frontal and cerebellar structures in subjects with WS may contribute to their relative linguistic competence.

As reviewed above, subjects with WS, in marked contrast to subjects with DS, are sociable and affectively sensitive, and they use affective linguistic devices at least as frequently as controls do, perhaps excessively. The present finding of relative sparing of structures in the limbic system in WS is interesting in light of these observations. Perhaps a neurodevelopmental course favoring certain limbic structures over other cortical and subcortical structures results in relative prominence of affective strategies in communication. The normal symmetry observed in temporal limbic regions is further evidence of normal maturation and specialization in this system.

The results in DS are consistent with earlier reports of the gross brain morphologic characteristics of these subjects. Cerebral hypofrontality, cerebellar hypoplasia, and even relatively normal appearance of brain-stem structures have been noted in autopsy studies.<sup>28-30</sup> This is the first report, to our knowledge, of normal volumes of thalamus and lenticular nuclei in subjects with DS who are definitely microcephalic. The pattern of poor development of cerebellar, limbic, and neocortical (particularly frontal) systems may underlie the impoverishment of language and social-affective function in these subjects. The relatively preserved brain-stem and posterior cortical structures may

provide the basis for superior global form and spatial integrative functions in subjects with DS relative to subjects with WS.

Functional distinctions between ventrally and dorsally lying cortical systems have been described, particularly within the visual system.<sup>31,32</sup> Form, color, and face processing functions have been associated with a ventral cortical system with predominant input from the parvocellular pathway, while spatial integrative and motion processing functions have been associated with dorsal structures in the temporoparietal junction (related to the magnocellular pathway).<sup>33-35</sup> In some ways, the spared and impaired visuospatial functions in WS appear to respect these distinctions. Face processing is spared, while spatial integrative functions are markedly affected. Perhaps cortical systems subserving the slower, but higher-resolution, processes associated with the parvocellular pathway are selectively spared in WS, while in DS the two pathways are both affected. Selective effects on the magnocellular system have been hypothesized to account for dyslexia, another developmental disorder.<sup>36</sup> Future studies with the rapidly improving brain-imaging technologies will permit examination of more specific cortical structures within these two cortical subsystems.

This study was supported by funds from the Medical Research Service of the Department of Veterans Affairs (Dr. Jernigan), by the National Institute for Neurological Disorders and Stroke Multidisciplinary Research Center for the Study of the Neurological Basis of Language, Learning, and Behavior Disorders in Children (Grant NS22343), and by National Institutes of Health grants HD26022 and DC01289 (Dr. Bellugi).

We are grateful to Paul P. Wang, MD, and William C. Heindel, PhD, for helpful discussions.

#### References

1. Williams JCP, Barrett-Boyes BC, Lowe JB. Supraaortic stenosis. *Circulation*. 1961;24:1311-1318.
2. Von Arnim G, Engel P. Mental retardation related to hypercalcaemia. *Dev Med Child Neurol*. 1964;6:366-377.
3. Jones KL, Smith DW. The Williams elfin faces syndrome: a new perspective. *J Pediatr*. 1975;86:718-723.
4. Preus M. The Williams syndrome: objective definition and diagnosis. *Clin Genet*. 1984;25:422-428.
5. MacDonald GW, Roy DL. Williams syndrome: a neuropsychological profile. *J Clin Exp Neuropsychol*. 1988;10:125-131.
6. Crisco JJ, Dobbs JM, Mulhern RK. Cognitive processing of children with Williams syndrome. *Dev Med Child Neurol*. 1988;30:650-656.
7. Udwin O, Yule W. A cognitive and behavioural phenotype in Williams syndrome. *J Clin Exp Neuropsychol*. 1991;13:232-244.
8. Bellugi U. Language and cognition: what the hands reveal about the brain: Presidential Special Lecture, Society for Neuroscience Annual Meeting. *Soc Neurosci Abstr*. 1991;17(parts 1 and 2):xii. Abstract.
9. Bellugi U, Bihrlé A, Jernigan T, Trauner D, Doherty S. Neuropsychological, neurological, and neuroanatomical profile of Williams syndrome. *Am J Med Genet Suppl*. 1990;6:115-125.
10. Bellugi U, Bihrlé A, Neville H, Jernigan TL, Doherty S. Language cognition and brain organization in a neurodevelopmental disorder. In: Gunnar M, Nelson C, eds. *Developmental Behavioral Neuroscience*. Hillsdale, NJ: Erlbaum Press; 1992:201-232.
11. Bellugi U, Sabo H, Vaid J. Spatial deficits in children with Williams syndrome. In: Stiles-Davis J, Kritchevsky M, Bellugi U, eds. *Spatial Cognition: Brain Bases and Development*. Hillsdale, NJ: Erlbaum Press; 1988:273-298.
12. Bihrlé AM. *Visuospatial Processing in Williams and Down Syndrome*. San Diego, Calif: University of California and San Diego State University; 1990. Dissertation.
13. Bihrlé AM, Bellugi U, Delis D, Marks S. Seeing either the forest or the trees: dissociation in visuospatial processing. *Brain Cogn*. 1989;11:37-49.
14. Reilly J, Klima ES, Bellugi U. Once more with feeling: affect and language in atypical populations. *Dev Psychopathol*. 1990;2:367-391.
15. Beery KE, Buktenica NA. *Developmental Test of Visual-Motor Integration*. Cleveland, Ohio: Modern Curriculum Press; 1967.
16. Delis DC, Bihrlé AM. Fractionation of spatial cognition following focal and diffuse brain damage. In: Ardila A, Ostrosky F, eds. *Brain Organization of Language and Cognitive Processes: New Directions of Research*. New York, NY: Plenum Press; 1989:17-35.

17. Delis DC, Kiefner MG, Fridlund AJ. Visuospatial dysfunction following unilateral brain damage: dissociations in hierarchical and hemispatial analysis. *J Clin Exp Neuropsychol*. 1988;10:421-431.
18. Delis DC, Robertson LC, Efron R. Hemispheric specialization of memory for visual hierarchical stimuli. *Neuropsychologia*. 1986;24:205-214.
19. Jernigan TL, Bellugi U. Anomalous brain morphology on magnetic resonance images in Williams syndrome and Down syndrome. *Arch Neurol*. 1990;47:529-533.
20. Bellugi U, Bihrlle AM, Marks S, Jernigan T, Culler F. Neuropsychological and neurobiological account of a disorder. *Soc Neurosci Abstr*. 1987;13:654. Abstract.
21. Culler FL, Jones KL, Deftos LJ. Impaired calcitonin secretion in patients with Williams syndrome. *J Pediatr*. 1985;107:720-723.
22. Jernigan TL, Tallal P. Late childhood changes in brain morphology observable with MRI. *Dev Med Child Neurol*. 1990;32:379-385.
23. Jernigan TL, Press GA, Hesselink JR. Methods for measuring brain morphologic features on magnetic resonance images: validation and normal aging. *Arch Neurol*. 1990;47:27-32.
24. Jernigan TL, Archibald SL, Berhow MT, Sowell EA, Foster DS, Hesselink JR. Cerebral structure on MRI, I: localization of age-related changes. *Biol Psychiatry*. 1991;29:55-67.
25. Jernigan TL, Schafer K, Butters N, Cermak LS. Magnetic resonance imaging of alcoholic Korsakoff patients. *Neuropsychopharmacology*. 1991;4:175-186.
26. Jernigan TL, Trauner DA, Hesselink JR, Tallal PA. Maturation of human cerebrum observed in vivo during adolescence. *Brain*. 1991;114:2037-2049.
27. Leiner HC, Leiner AL, Dow R. Does the cerebellum contribute to mental skills? *Behav Neurosci*. 1986;100:443-454.
28. Benda CE. Mongolism. In: Minckler J, ed. *Pathology of the Nervous System*. New York, NY: McGraw-Hill International Book Co; 1971;2:1361-1371.
29. Coyle JT, Oster-Granite ML, Gearhart JD. The neurobiologic consequences of Down syndrome. *Brain Res Bull*. 1986;16:773-787.
30. Schmidt-Sidor B, Wisniewski KE, Shepard TH, Sersen EA. Brain growth in Down syndrome subjects 15 to 22 weeks of gestational age and birth to 60 months. *Clin Neuropathol*. 1990;9:181-190.
31. Newcombe F, Russell WR. Dissociated visual perceptual and spatial deficits in focal lesions of the right hemisphere. *J Neurol Neurosurg Psychiatry*. 1969;32:73-81.
32. Ungerleider LG, Mishkin M. Two cortical visual systems. In: Ingle DJ, Goodale MA, Mansfield RJW, eds. *Analysis of Visual Behavior*. Cambridge, Mass: MIT Press; 1982:549-586.
33. Kandel ER. Perception of motion, depth, and form. In: Kandel ER, Schwartz JH, Jessell TM, eds. *Principles of Neural Science*. 3rd ed. New York, NY: Elsevier Science Publishing Co Inc; 1991:440-466.
34. Goldman-Rakic PS. Topography of cognition: parallel distributed networks in primate association cortex. *Ann Rev Neurosci*. 1988;11:137-156.
35. Livingstone MS, Hubel DH. Psychophysical evidence for separate channels for the perception of form, color, movement, and depth. *J Neurosci*. 1987;7:3416-3468.
36. Livingstone MS, Rosen GD, Drislane FW, Galaburda AM. Physiological and anatomical evidence for a magnocellular defect in developmental dyslexia. *Proc Natl Acad Sci U S A*. 1991;88:7943-7947.