

Neural dissociation in the production of lexical versus classifier signs in ASL: Distinct patterns of hemispheric asymmetry

Gregory Hickok^{a,*}, Herbert Pickell^b, Edward Klima^b, Ursula Bellugi^b

^a Center for Cognitive Neuroscience, Department of Cognitive Sciences, University of California, 3151 Social Sciences Plaza, Irvine, Irvine, CA 92697, United States

^b Laboratory for Cognitive Neuroscience, Salk Institute for Biological Studies, United States

ARTICLE INFO

Article history:

Received 31 May 2007

Received in revised form 23 April 2008

Accepted 10 September 2008

Available online 19 September 2008

Keywords:

Sign language

Aphasia

ASL

Classifiers

ABSTRACT

We examine the hemispheric organization for the production of two classes of ASL signs, lexical signs and classifier signs. Previous work has found strong left hemisphere dominance for the production of lexical signs, but several authors have speculated that classifier signs may involve the right hemisphere to a greater degree because they can represent spatial information in a topographic, non-categorical manner. Twenty-one unilaterally brain damaged signers (13 left hemisphere damaged, 8 right hemisphere damaged) were presented with a story narration task designed to elicit both lexical and classifier signs. Relative frequencies of the two types of errors were tabulated. Left hemisphere damaged signers produced significantly more lexical errors than did right hemisphere damaged signers, whereas the reverse pattern held for classifier signs. Our findings argue for different patterns of hemispheric asymmetry for these two classes of ASL signs. We suggest that the requirement to encode analogue spatial information in the production of classifier signs results in the increased involvement of the right hemisphere systems.

© 2008 Elsevier Ltd. All rights reserved.

Lesion-based research on the hemispheric organization of sign language in deaf individuals has shown conclusively that the left hemisphere is dominant for fundamental aspects of sign language processing. These include production at the individual sign and sentence levels, verbatim repetition of signs and phrases, comprehension at the individual sign and sentence levels, and naming to confrontation (Hickok & Bellugi, 2001; Hickok, Bellugi, & Klima, 1998a; Hickok, Klima, & Bellugi, 1996; Hickok, Love-Geffen, & Klima, 2002). In other words, left hemisphere damage in deaf signers often leads to clinical aphasic deficits, whereas right hemisphere damage does not.

In this report we examine the hemispheric organization for processing a class of sign forms in American Sign Language (ASL), classifier signs, that have some unique properties and are not typically assessed on standard aphasia exams in signed or spoken language. Classifier signs are complex forms that can be used to specify a range of spatial information, relative location, movement path, movement manner, and object size and shape (see Emmorey, 2002 for a review). Classifier forms are typically comprised of two parts (1) a handshape configuration, where different handshapes can correspond to different semantic classes of object referents (e.g., people, vehicles, etc.), or to object shape-related properties (e.g., flat, narrow, etc.) and (2) a specification of the location and/or

movement of the referent, denoted by the location/movement of the hand(s) in signing space. The linguistic status of classifier forms is a matter of debate, but what is clear is that they differ from canonical lexical signs in that they can encode information, spatial information in particular, non-categorically. Whereas a lexical sign like ON can specify that one object is on top of another, a classifier sign can specify the precise relation between the objects, for example, that the two objects are slightly askew. Likewise, whereas a lexical sign like DRIVE-TO can indicate that a vehicle was driven from one place to another, a classifier sign can convey more detailed information about the route traversed, for example that it was curvy and uphill (Fig. 1).

Thus, a classifier sign can encode a great deal of analogue spatial/topographic information about a referent that is not possible with a single lexical sign. Because of this, several investigators have speculated that the right hemisphere may be more involved in processing classifier signs than in processing canonical lexical signs (Hickok, Bellugi, & Klima, 1998b; Poizner, Klima, & Bellugi, 1987), and a handful of recent functional imaging studies have provided some evidence supporting this idea. For example, a PET study by Emmorey et al. (2002), found that deaf native signers activated parietal regions bilaterally when describing spatial relations using ASL classifier signs (compared to naming objects). This result contrasted with an earlier study (Damasio et al., 2001), which found left dominant activation in English speakers for naming spatial relations with English prepositions. A follow-up PET experiment by this same group (Emmorey et al., 2005), at least partially

* Corresponding author. Tel.: +1 949 824 1409.

E-mail address: greg.hickok@uci.edu (G. Hickok).

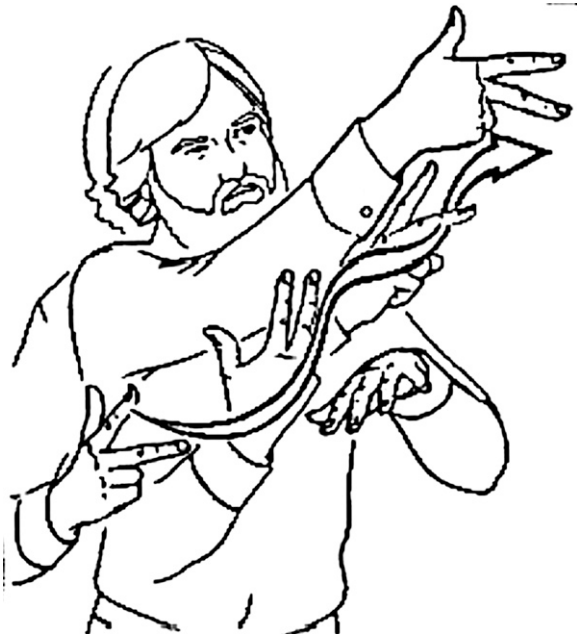

Fig. 1. Illustration of a classifier sign form. The handshape is the form used for vehicles. Movement shows the vehicle winding up a curvy hill. The details of the meaning of such an utterance (e.g., what type of vehicle, etc.) would depend on its lexical context.

confirmed this pattern of results in hearing bilingual (English and ASL) signers. While bilateral parietal activation was found both for naming spatial relations in English and describing spatial relations with ASL classifiers, activation in a right parietal region was more active for the ASL classifier condition than the English lexical preposition condition, suggesting more right hemisphere involvement for ASL classifiers than (English) lexical prepositions. See Campbell and Woll (2003), for additional discussion.

The present study was designed as a lesion-based test of the hypothesis that the right hemisphere is more involved in the production of ASL classifiers than in the production of lexical signs. As language production tends to be strongly left dominant in both signed and spoken language, particularly at the lexical level, such a finding would indicate that at least some aspects of language production may involve the right hemisphere to an extent not previously appreciated. Left or right hemisphere damaged (LHD versus RHD) signers were given a story narration task designed to elicit classifier signs. We made several predictions. First, because canonical aphasic deficits are typically associated with LHD but not RHD, we predicted that LHD signers would produce significantly fewer signs overall than RHD signers, and that this effect would be most prominent for lexical signs (because classifier sign production may be adversely affected in RHD). Second, we expected that LHD signers would make significantly more errors on the lexical signs they produced than RHD signers. And finally, we predicted that RHD signers would make proportionately more classifier sign errors than LHD signers.

1. Methods

This study was approved by the Institutional Review Boards of the Salk Institute for Biological Studies and the University of California, Irvine.

1.1. Subjects

Twenty-one, right-handed unilaterally brain damaged signers (13 with LHD, 8 with RHD) participated in the experiment. Prior to their brain injury, all were fluent signers of ASL which was their primary system of communication, and all but one

were deaf.¹ All participants had unilateral lesions confirmed by CT and/or MRI. All participants were tested in a chronic state of their disease (>1 year post event). At the time of testing, subjects were alert and oriented, and fully understood the nature of the task. Left and right hemisphere damaged groups did not differ significantly in onset of deafness ($p = .21$), age at testing ($p = .59$), or years of signing experience ($p = .86$). There was a trend for LHD signers to have had a later exposure to sign language than the RHD signers ($t(15) = 1.799$, $p = .09$, 2-tailed), but this difference does not predict our findings (see discussion below and Fig. 2). Means, standard deviations, and p -values for statistical contrasts (t -tests, 2-tailed) are provided in Table 1 along with additional biographical and lesion-related information.

1.2. Narrative production task

A narrative production task was employed using a wordless picture book story, the "Paint Story" designed to elicit both classifier and lexical signs (Fig. 3). Subjects were shown one page at a time and asked to provide a narrative description of what they saw. Specifically subjects were instructed to look at the pictures in the "story book" and describe what they see happening in each picture. Responses were videotaped for later scoring. Testing was carried out by native deaf signers (exposed to ASL from birth).

1.3. Scoring and analysis

Two native signers counted the number of lexical signs versus classifier signs in each subject's narrative, then categorized each utterance as either a correct production or an error. Errors on lexical signs included phonemic paraphasias (errors in the sign form such as handshape, location, motion, or orientation) and lexical paraphasias (substituting one sign for another) (Hickok & Bellugi, 2001); errors on classifier signs included handshape selection errors, location errors, and motion path errors.² Inter-rater reliability was better than 96% in independent scoring. Disagreements were resolved via group discussion. Error types within both classes of sign utterances were collapsed to yield four data points for each subject: total number of lexical signs produced, total number of classifier signs produced, proportion of lexical errors relative to lexical signs attempted, and proportion of classifier errors relative to classifier signs attempted.

2. Results

Separate multivariate analyses of variance (MANOVAs) were used to examine raw sign count data and proportional error data. Both analyses incorporated lesion site (LHD versus RHD) as the independent variable, and sign/error type (lexical versus classifier) as the two dependent variables. The MANOVA on the raw count data showed a significant effect of lesion site ($F(1,19) = 9.705$, $p = .006$) indicating that LHD signers produced significantly fewer signs overall, and a significant effect of sign type ($F(1,19) = 41.013$, $p < .001$), indicating that significantly more lexical signs were produced than classifier signs overall. The latter finding is of limited interest given that lexical signs are much more frequent than classifier signs (~5:1 ratio) in normal ASL narratives (Morford & Macfarlane, 2003). The interaction between lesion site and sign type was also significant ($F(1,19) = 8.948$, $p = .008$). This interaction was attributable to the fact that LHD signers produced significantly fewer lexical signs than did RHD signers ($p = .038$). LHD and RHD signers did not differ in the number of classifier signs produced ($p = .24$). Thus, analysis of the raw sign counts confirmed our first prediction that LHD signers would produce fewer signs overall, with the difference being realized primarily in lexical signs. See Fig. 4.

¹ The hearing participant was bilingual and native in both English and ASL, having been exposed to both languages since birth. Thus, including a hearing signer in this study is equivalent to including a bilingual participant in a study of spoken language aphasia. We acknowledge that deafness itself may have implications for brain organization of language and therefore including a hearing signer may influence our findings somewhat. However, our findings do not change qualitatively if the hearing signer is removed from the analysis.

² Note that on the surface, errors on lexical signs (which are often classified as phonemic vs. lexical/semantic paraphasia) and errors on classifier signs look very similar, and indeed could be identical superficially. The point of this analysis is to determine whether such errors occur differentially depending on the underlying sign type.

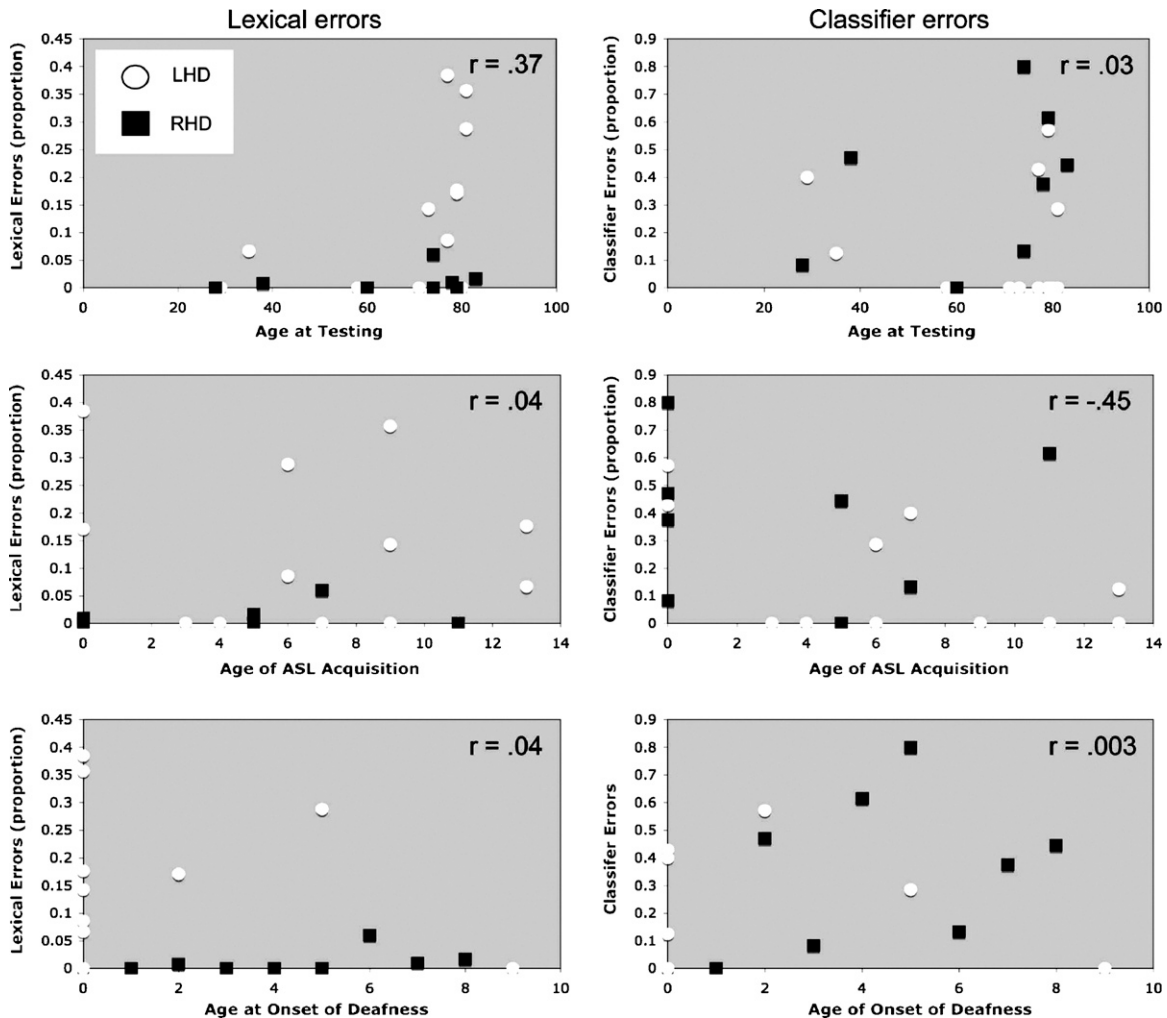


Fig. 2. Scatter plots showing error rates for lexical (top) and classifier (bottom) signs plotted against age at onset of deafness. r -values are for left and right brain damage subjects combined. These graphs indicate that the findings reported below cannot be explained in terms of age of testing, age of acquisition, or age of onset of deafness.

The MANOVA on the proportional error data (lexical errors/total lexical signs produced; classifier errors/total classifier signs produced) yielded a significant effect of error type ($F(1,19) = 11.621$, $p = .003$), indicating that classifier errors were more frequent (proportionally) than lexical errors overall. There was no main effect of lesion site ($p = .399$) overall, but there was a significant interaction of lesion site and error type ($F(1,19) = 10.300$, $p = .005$). Planned comparisons showed that RHD signers made significantly more classifier than lexical errors ($p = .005$), that LHD signers made significantly more lexical errors than did RHD signers ($p = .006$), and that RHD signers made more classifier errors than did LHD signers (marginally significant at $p = .03$, with a Bonferroni-corrected threshold of 0.01). There was no difference between lexical and classifier errors among LHD signers ($p = .86$). Thus, the analysis of error rates confirmed our predictions that LHD signers would make more lexical errors than RHD signers, whereas RHD signers would make more classifier errors. See Fig. 5.

As noted above, our left and right lesioned groups were not significantly different on variables such as age at testing, age of ASL acquisition, and age of onset of deafness. However, there was a trend for LHD signers to have been exposed to ASL later than our RHD signers. To ensure this variable is not sufficient to explain our findings, we examined the relation between age of ASL exposure and error rates on lexical and classifier signs (Fig. 2). There was no correlation between age of exposure to ASL and lexical error rate ($r = .04$,

$p = .85$), but there was a significant correlation between age of ASL exposure and classifier error rate ($r = .46$, $p = .03$). However, as can be appreciated in Fig. 2, this is the reverse relation that one might expect with fewer errors among subjects who acquired ASL later. Critically, there are a number of subjects at the same level on one axis yet showing the full range of variation on the other, indicating that some other important factor is underlying performance, i.e., left versus right hemisphere damage (Fig. 5).

3. Discussion

Although there has been speculation for some time that the right hemisphere may be involved in the processing of ASL classifier signs, the present report provides the first solid evidence supporting this idea. While RHD signers made very few lexical errors, consistent with previous reports on RHD signers' performance on standard sign language assessment tests, they committed a significant number of classifier errors. This dissociation between lexical and classifier ASL forms in RHD signers suggests that the right hemisphere is differentially involved in the production of these two classes of signs, specifically that it is substantially more involved in classifier production than lexical sign production. Data from LHD signers confirms previous findings regarding lexical sign production in that they made lexical errors at a relatively high rate (~13% error rate). However, LHD signers committed classifier errors at

Table 1
Subject biographical information. LHD, left hemisphere damage; RHD, right hemisphere damage.

	Age of sign exposure	Onset deafness	Gender	Age at testing	Years of signing experience	Imaging modality	Lesion size/location	Lesion etiology
Left lesioned								
LHD101	6	5	M	81	75	CT	Large/frontal-parietal	Ischemic Infarct
LHD106	13	0	F	35	22	CT	Moderate/frontal-temporal	Ischemic Infarct
LHD108	0	0	M	77	77	CT	Moderate/frontal-temporal-parietal	Ischemic Infarct
LHD110	3	0	M	58	55	CT	Basal ganglia	Hemorrhage
LHD113	9	1	M	81	72	CT	Moderate/subcortical	Hemorrhage
LHD114	13	0	M	79	66	CT	Caudate/basal ganglia	Hemorrhage
LHD121	7	1	M	29	22	CT	Moderate/frontal-parietal	Hemorrhage ^a
LHD130	0	2	F	79	79	MRI	Moderate/inferior-posterior frontal	Ischemic Infarct
LHD131	9	1	F	73	64	MRI	Moderate/frontal-parietal	Ischemic Infarct
LHD132	11	0	F	79	68	MRI	Large/frontal-temporal-parietal	Ischemic Infarct
LHD133	4	0	M	71	67	MRI	Moderate/inferior frontal-parietal	Hemorrhage
LHD135	6	0	F	77	71	MRI	Moderate/frontal-parietal	Ischemic Infarct
LHD151	9	9	M	80	71	MRI	Large/frontal-parietal	Ischemic Infarct
Mean	6.92	1.46		69.15	62.23			
Standard deviation	4.33	2.67		17.64	18.87			
Right lesioned								
RHD205	5	0	M	60	55	MRI	Large/frontal-temporal-parietal	Ischemic Infarct
RHD207	0	n/a ^b	F	38	38	MRI	Moderate/superior parietal-occipital	Hemorrhage ^a
RHD213	0	0	M	28	28	MRI	Moderate/anterior-superior-parietal	Tumor resection ^a
RHD214	11	2	F	79	68	MRI	Moderate/superior frontal-parietal	Ischemic Infarct
RHD216	0	0	M	74	74	MRI	Large/frontal-temporal-parietal	Ischemic Infarct
RHD221	7	1	M	74	67	MRI	Large/frontal-temporal-parietal	Ischemic Infarct
RHD224	0	0	F	78	78	MRI	Moderate/parietal-occipital	Ischemic Infarct
RHD225	5	0	F	83	78	MRI	Large/temporal-parietal	Ischemic Infarct
Mean	3.50	0.43		64.25	60.75			
Standard deviation	4.17	0.79		20.60	18.84			
LHD vs. RHD <i>p</i> -value	0.091641	0.213904		0.58554	0.8635979			

^a Surgical intervention.

^b Hearing bilingual (English and ASL).

statistically the same rate (~14%). This finding confirms previous evidence showing left hemisphere involvement in lexical sign production, and additionally shows that it is involved in classifier form production.

Comparison of performance across LHD and RHD groups provides evidence regarding the relative contributions of the two hemispheres in lexical versus classifier form production. LHD signers made significantly more lexical errors than RHD signers (the

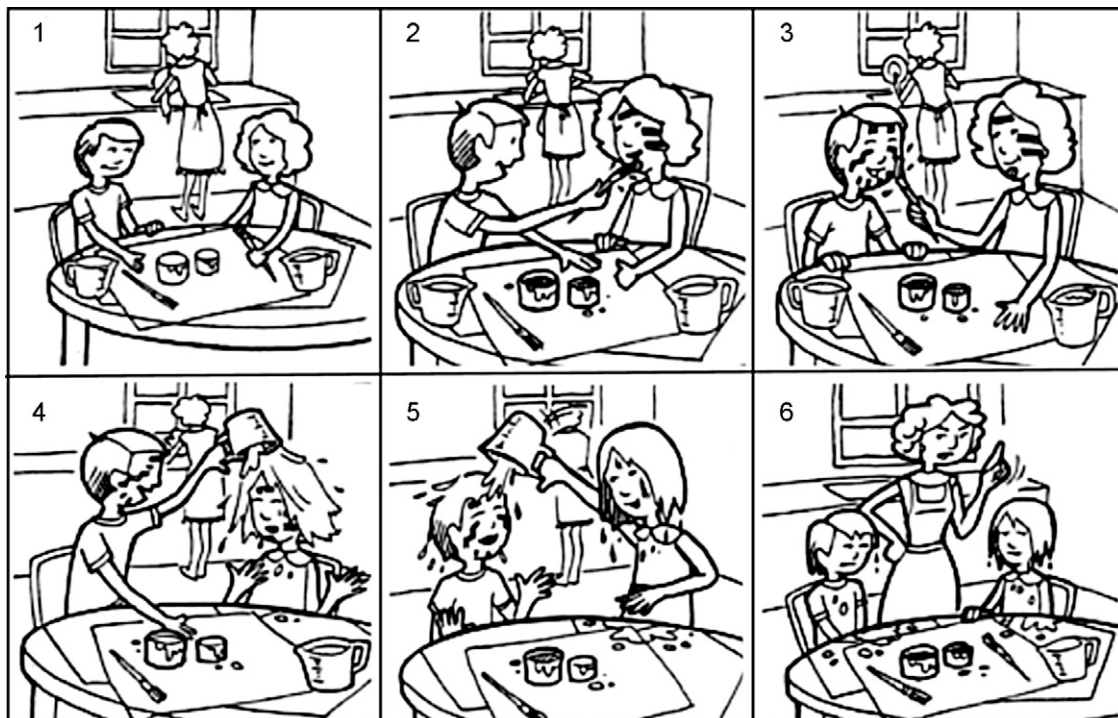


Fig. 3. The “Paint Story.”

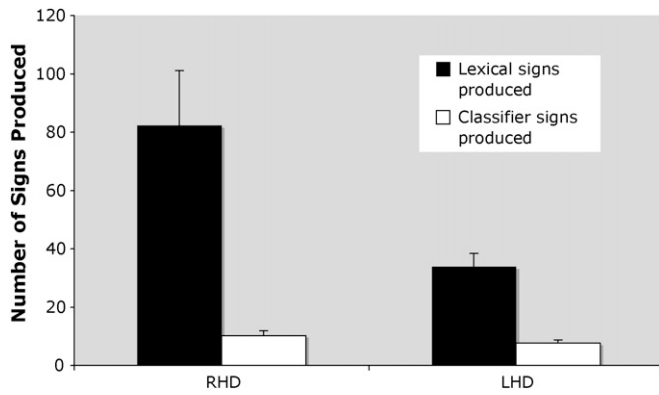


Fig. 4. Mean number of lexical versus classifier signs elicited in the Paint Story task in left hemisphere damaged (LHD) versus right hemisphere damaged (RHD) participants. Bars represent standard error.

error rate for the later being negligible at 1%), suggesting a strong left hemispheric dominance in the neural organization for lexical sign production. The reverse pattern held for classifier form production, with RHD signers making more classifier errors than LHD signers. However, unlike the pattern for lexical signs, which was associated with damage to only one hemisphere (namely the left), errors on classifier forms were associated with damage to either the left or right hemisphere. This suggests bilateral involvement in classifier form production, but with perhaps a right hemisphere dominance. It is possible that left versus right hemisphere injury disrupts different aspects of classifier form production. For example, it has been suggested that classifier forms represent blends between gesture and sign (Liddell, 2003; Schembri, Jones, & Burnham, 2005). Unfortunately, our corpus of errors was not sufficiently large to allow a comparison of error types within the classifier system across left and right hemisphere damaged groups (no clear patterns were evident).

The neural dissociation between lexical and classifier forms found in the present study provides strong evidence for distinct representations underlying these classes of ASL signs. An attractive hypothesis is that the handshape component of classifiers, which tends to be categorical and which has been suggested to be morphemic (Emmorey, 2002), is represented and processed in a manner similar to lexical signs and is left hemisphere dominant, whereas the analogue movement/spatial component of classifiers is represented and/or processed by non-lexical systems that demand greater involvement of the right hemisphere. This would

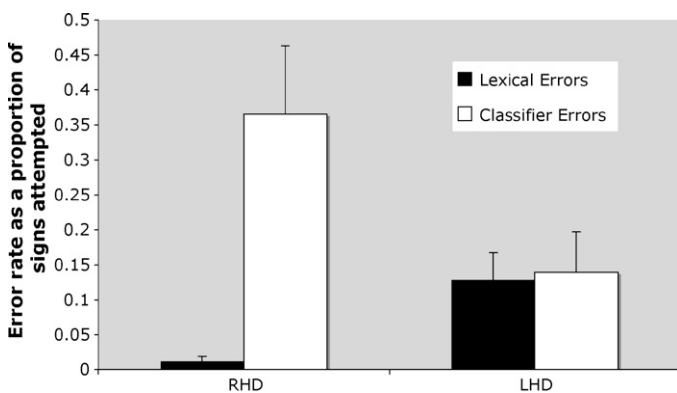


Fig. 5. Mean error rate in left hemisphere damaged (LHD) versus right hemisphere damaged (RHD) signers expressed as a proportion of signs attempted: lexical sign errors/lexical signs produced and classifier sign errors/classifier signs produced. Bars represent standard error.

also be consistent with the hypothesis that classifier forms are blends between linguistic and non-linguistic gestures (Liddell, 2003; Schembri et al., 2005). Such an account could explain the observed dissociations, although future work will be needed to test this hypothesis.

Our results are consistent with imaging based work on the production of lexical and classifier forms. Existing studies on the production of lexical signs show left dominant activation (Corina, San Jose-Robertson, Guillemin, High, & Braun, 2003; McGuire et al., 1997; Petitto et al., 2000; San Jose-Robertson, Corina, Ackerman, Guillemin, & Braun, 2004) consistent with our observation that left but not right hemisphere injury resulted in an increase in the number of lexical errors. Imaging studies of classifier production, however, has suggested that the right hemisphere may be more involved in the production of these forms (Emmorey et al., 2005).

Finally, our results have potential clinical implications concerning the detection of language deficits in unilaterally brain-injured signers. As standard aphasia assessment tools do not explicitly assess the production of classifier forms, important language deficits may be missed in the assessment of sign language aphasia, not only for LHD signers, but RHD signers as well. Further, while the effects of many sign language deficits are well-known to affect the day-to-day communication ability of affected signers (Corina, 1998; Hickok & Bellugi, 2001; Poizner et al., 1987), the potential practical effects of deficits in classifier sign processes remains to be assessed.

In sum, patterns of errors in a narrative production task following left versus right hemisphere damage, suggest a distinction in the neural organization of lexical signs versus classifier forms. Lexical sign production appears to be strongly left dominant, whereas the production of classifier forms relies on both hemispheres, with a right dominance for at least some aspects of classifier production. This increased right hemisphere involvement for classifiers, as opposed to lexical signs, may reflect the analogue nature of the spatial encoding of classifier signs.

References

- Campbell, R., & Woll, B. (2003). Space is special in sign. *Trends in Cognitive Sciences*, 7, 5–7.
- Corina, D. (1998). The processing of sign language: Evidence from aphasia. In *Handbook of neurolinguistics*. San Diego: Academic Press, pp. 313–329.
- Corina, D. P., San Jose-Robertson, L., Guillemin, A., High, J., & Braun, A. R. (2003). Language lateralization in a bimanual language. *Journal of Cognitive Neuroscience*, 15(5), 718–730.
- Damasio, H., Grabowski, T. J., Tranel, D., Ponto, L. L., Hichwa, R. D., & Damasio, A. R. (2001). Neural correlates of naming actions and of naming spatial relations. *Neuroimage*, 13(6 Pt 1), 1053–1064.
- Emmorey, K. (2002). *Language, cognition, and the brain: Insights from sign language research*. Mahwah, NJ: Lawrence Erlbaum and Associates.
- Emmorey, K., Damasio, H., McCullough, S., Grabowski, T., Ponto, L. L., Hichwa, R. D., et al. (2002). Neural systems underlying spatial language in American Sign Language. *Neuroimage*, 17(2), 812–824.
- Emmorey, K., Grabowski, T., McCullough, S., Ponto, L. L., Hichwa, R. D., & Damasio, H. (2005). The neural correlates of spatial language in English and American Sign Language: A PET study with hearing bilinguals. *Neuroimage*, 24(3), 832–840.
- Hickok, G., & Bellugi, U. (2001). The signs of aphasia. In R. S. Berndt (Ed.), *Handbook of neuropsychology* (2nd ed., Vol. 3, pp. 31–50). New York: Elsevier.
- Hickok, G., Bellugi, U., & Klima, E. S. (1998a). The neural organization of language: Evidence from sign language aphasia. *Trends in Cognitive Sciences*, 2, 129–136.
- Hickok, G., Bellugi, U., & Klima, E. S. (1998b). What's right about the neural organization of sign language? A perspective on recent neuroimaging results. *Trends in Cognitive Sciences*, 2, 465–468.
- Hickok, G., Klima, E. S., & Bellugi, U. (1996). The neurobiology of signed language and its implications for the neural basis of language. *Nature*, 381, 699–702.
- Hickok, G., Love-Geffen, T., & Klima, E. S. (2002). Role of the left hemisphere in sign language comprehension. *Brain and Language*, 82, 167–178.
- Liddell, S. K. (2003). Sources of meaning in ASL classifier predicates. In K. Emmorey (Ed.), *Perspectives on classifier constructions in sign languages* (pp. 199–220). Mahwah, NJ: Erlbaum.
- McGuire, P. K., Robertson, D., Thacker, A., David, A. S., Kitson, N., Frackowiak, R. S., et al. (1997). Neural correlates of thinking in sign language. *Neuroreport*, 8, 695–698.

- Morford, J., & Macfarlane, J. (2003). Frequency characteristics of American Sign Language. *Sign Language Studies*, 3, 213–225.
- Petitto, L. A., Zatorre, R. J., Gauna, K., Nikelski, E. J., Dostie, D., & Evans, A. C. (2000). Speech-like cerebral activity in profoundly deaf people processing signed languages: implications for the neural basis of human language. *Proceedings of the National Academy of Sciences of the United States of America*, 97(25), 13961–13966.
- Poizner, H., Klima, E. S., & Bellugi, U. (1987). *What the hands reveal about the brain*. Cambridge, MA: MIT Press.
- San Jose-Robertson, L., Corina, D. P., Ackerman, D., Guillemin, A., & Braun, A. R. (2004). Neural systems for sign language production: mechanisms supporting lexical selection, phonological encoding, and articulation. *Human Brain Mapping*, 23(3), 156–167.
- Schembri, A., Jones, C., & Burnham, D. (2005). Comparing action gestures and classifier verbs of motion: evidence from Australian Sign Language, Taiwan Sign Language, and nonsigners' gestures without speech. *Journal of Deaf Studies and Deaf Education*, 10(3), 272–290.